

## Invited Review

# Epidermal Langerhans cells in infectious diseases

Félix J. Tapia, Gisela Cáceres-Dittmar, Lourdes Acuña and Walter Mosca

Instituto de Biomedicina, Caracas, Venezuela

**Key words:** Langerhans cells, Leishmaniasis, Leprosy, Skin immune system

### Introduction

Paul Langerhans was one of the most brilliant scientific observers of his time, contributing considerably not only to medicine but also to zoology by describing new species of invertebrates (De Panfilis, 1988). He was a medical student at the Berlin Pathological Institute when he discovered in 1868 the epidermal cells that bear his name. He believed that these gold chloride-positive midepidermis dendritic cells were intra-epidermal receptors for extracutaneous signals to the nervous system (Langerhans, 1868). This neural hypothesis prevailed for almost a century. Not until 1965, when the morphological identity between Langerhans cells (LC) and histiocytes X cells was described, was a possible mesenchymal derivation for LC postulated (Basset and Turiaf, 1965). In 1966, Campo-Aasen and Pearse demonstrated cytochemically that epidermal LC share specific enzymes with macrophages. Further accumulated evidence supported the striking similarities between LC and macrophage/monocytes, including the expression of Fc and C3 receptors (Stingl et al., 1977), expression of Major Histocompatibility Complex class II (Ia) molecules (Klareskog et al., 1977; Rowden et al., 1977), ability to migrate (Silberberg, 1973) and the *in vitro* ability to stimulate allogeneic T-cells (Stingl et al., 1978). LC also produce interleukin-1 (IL-1), previously denoted in the skin as epidermal cell-derived thymocyte-activating factor (ETAF) (Sauder et al., 1984). The IL-1 serves as the second signal in triggering the production of interleukin-2 (IL-2) by T-helper cells, thus amplifying ongoing T-cell responses.

### Morphology and specific cell markers

Birbeck et al. (1961) observed at the electron microscope level a unique cytoplasmic granule within LC. This distinctive and characteristic structure, the Birbeck granule, is usually a cup-shaped organelle that at one end contains a small vesicle, which in cross sections appears as the characteristic rod or racket structure.

At the light microscopic level LC cannot be identified using conventional histological stains. However, various histochemical or immunocytochemical markers have been used for LC characterization. For many years, membrane-bound ATPase has been widely used in the characterization of LC. However, this cytochemical staining is also present in other cells of the monocyte-macrophage series and interpretation is difficult when the number of cells is high, as in the case of many pathological conditions (Wolff, 1972; Tapia et al., 1988). Other cytochemical procedures such as zinc iodide, cobalt chloride and paraphenylenediamine, have had some applications in the characterization of LC (Niebauer, 1968; Juhlin and Shelley, 1977; Rodríguez and Caorsi, 1978).

The use of monoclonal antibodies and immunocytochemical procedures has allowed the precise characterization of the different cell subsets involved in immune mechanisms. Under normal conditions LC are the only Ia-positive cells in the epidermis (Rowden et al., 1977; Klareskog et al., 1977). However, under certain pathological conditions the keratinocytes can also express these antigens on their surface (De Panfilis and Allegra, 1979; Auböck et al., 1986; Gross et al., 1988). Fithian et al. (1981) were the first to develop a monoclonal antibody directed to a membrane-associated antigen present in human LC and in about 70% of thymocytes. This antigen, referred to as the CD1 molecule (formerly known as T6), can be recognized by various monoclonal antibodies. The availability of anti-CD1 antibodies has contributed to understanding the role of LC in the generation of immune responses involving the skin.

After the Second International Workshop on Human Leucocyte Differentiation Antigens (Haynes, 1986), the CD1 complex was divided into 3 different molecular forms based on differences in molecular weight, cell distribution and specific monoclonal antibodies (Table 1). The CD1a (gp49), CD1b (gp45) and CD1c (gp43) are universally coexpressed in cortical thymocytes (McMichael et al., 1979; Olive et al., 1984; Amiot et al., 1986). In the skin, the three CD1 antigens are coexpressed in dermal indeterminate cells under pathological conditions; in contrast, epidermal LC only coexpressed CD1a and CD1c molecules (Murphy, 1985; Schmitt et al., 1987; Berti et al., 1988; Dezutter-Dambuyant, 1988). It has also been demonstrated that a subgroup of B lymphocytes expressed the CD1c molecule (Small et al., 1987).

Table 1.

General characteristics of the CD1 molecules.			
Molecular form	Mw	Monoclonal antibodies	Cells recognized
CD1a	49 kd	OKT6, Leu-6, Na134, BL-6	thymocytes, Langerhans cells, indeterminate cells.
CD1b	45 kd	NuT2, 4A7.6, WM25	thymocytes, indeterminate cells.
CD1c	43 kd	M241, L161	thymocytes, Langerhans cells, B-cell subset, indeterminate cells.

Human CD1 molecules are MHC class I antigens encoded by a new family of MHC-related genes located in chromosome 1 (Martin et al., 1986, 1987). The CD1a antigen may be part of a receptor since they are internalized throughout organelles which are characteristic of receptor-mediated endocytosis (Hanau et al., 1987).

Other LC markers include the mesenchymal intermediate filament vimentin (Fig. 1) (Löning et al., 1982; De Waal et al., 1984) and the S-100 protein (Cocchia et al., 1981; Nakajima et al., 1982), which have been used for the identification of LC or at least a subgroup of them in various animals.

Recently, Kraal et al. (1986) have developed a monoclonal antibody, the NLDC-145, which can recognize epidermal LC, veiled cells and interdigitating cells in mice, providing further evidence for a close relationship between these cell types.

#### Ontogeny of epidermal Langerhans cells

For many years the origin of LC was a matter of debate. Based on their dendritic form and gold chloride positivity many people believed they were part of the nervous system (Ferreira-Márques, 1951). Others thought LC were degenerated melanocytes (Billingham




Fig. 1. Epidermal dendritic cells immunoreactive to the intermediate filament vimentin (arrow) in the skin of the armadillo *Dasypus novencintus*. Bar = 10  $\mu$ m.

and Medawar, 1953). The work of Basset and Turiaf (1965) showing that histiocytes X cells were histiocytologically indistinguishable from epidermal LC provided the first suggestive evidence for a mesenchymal origin of the LC. Further works (Katz et al., 1979; Frelinger et al., 1979) showed that murine LC originate from a mobile pool of bone marrow-derived precursor cells. Recently, the bone marrow origin has been shown unequivocally for human LC (Pelletier et al., 1984).

Goordyal and Isaacson (1985) demonstrated the presence of cells with the phenotype characteristics of LC in culture monocyte colonies derived from human bone marrow. These cells were positive to peanut agglutinin (PNA) and also coexpressed the CD1a (LC and thymocytes), CD11 (mature monocytes) and CD14 (myelomonocytes) differentiation antigens. Gothelf et al. (1986) considered these cells as LC precursors, even though they lacked Birbeck granules.

CD1a-positive cells have also been found in normal peripheral blood suggesting that LC precursors migrate from the bone marrow to the epidermis via the blood vessels (Dezutter-Dambuyant et al., 1984; Wood et al., 1984). Recent findings demonstrated that the number of CD1a-positive cells increases in the peripheral blood of burn and trauma patients (Wood et al., 1984; Gothelf et al., 1988). These cells, which possess most of the morphological characteristics of LC, lack Birbeck granules, suggesting that they may appear after exposure to the epidermal microenvironment.

Several studies have shown that LC do divide in the epidermis, thus ending the general belief that they were cells in transit through the epidermis. The first investigations based on  $^3$ H-thymidine incorporation demonstrated that murine, and human and guinea pig LC entered S-phase in the epidermis (Giacometti and Montagna, 1967; MacKenzie, 1975; Gschnait and Brenner, 1979). More recently, Czernielewski et al. (1985, 1987), using immunocytochemical procedures, have shown that CD1a-positive LC in the epidermis are actively cycling and self-reproducing. These investigators estimated that the cell cycle time was 16.13 days

indicating that LC are a slow cycling cell population. Miyauchi and Hashimoto (1989) have been able to match LC morphological changes to cell cycle stages by using conventional ATPase staining, providing a new tool for the *in vivo* analysis of LC dynamics.

## Functions of Langerhans cells

### *The skin immune system*

Streilein (1978) used the term «skin-associated lymphoid tissues» (SALT) to describe the LC, skin T-lymphocytes, immunocompetent keratinocytes and the skin-draining peripheral lymph nodes, which included vascular high endothelial cells. This concept has been revised recently by Bos and Kapsenberg (1986) suggesting the term «skin immune system» (SIS) as a more appropriate. The SIS includes the dendritic antigen-presenting cells (LC, Granstein cells, indeterminate cells, veiled cells, and interdigitating cells), keratinocytes, tissue macrophages, neutrophilic granulocytes, mast cells, vascular endothelial cells, lymphatic endothelial cells and «homing» T-cells, but excludes the lymph node tissue. The SIS also includes other cell types such as fibroblasts, pericytes, eccrine and apocrine gland cells which may participate in the immune response to a given pathogen.

### *Antigen-presenting cells of the skin*

Macrophages were the first cells to be shown to act as antigen-presenting cells (Unanue, 1972, 1981). This ability for antigen presentation has also been described in LC, indeterminate cells, veiled cells, interdigitating and dendritic follicular reticulum cells (Silberberg-Sinakin et al., 1976; Klaus et al., 1980; Balfour et al., 1981; Faure et al., 1984).

Stingl et al. (1978) clearly demonstrated in guinea pigs that LC were necessary to induce a T-cell proliferative response to soluble protein antigens and chemical haptens. In human beings, LC are efficient antigen-presenting cells in lympho-proliferative assays using PPD, antigens, tricophytin and nickel sulfate as antigens, and T-cells from sensitized donors (Berle et al., 1982; Braathen and Thorsby, 1982). In addition, the use of the Mixed Skin Lymphocyte Reaction (MSLR) in which T-cells proliferate *in vitro* in response to allogeneic epidermal cells, has also demonstrated the importance of LC as antigen-presenting cells (Braathen and Thorsby, 1980; Czernielewski et al., 1983).

Recently, a new antigen-presenting cell has also been described in murine epidermis (Granstein et al., 1984). This cell type, denominated the Granstein cell, is resistant to ultraviolet irradiation, and is I-J restricted. These cells, which may be a subgroup of LC, are essential for the activation of suppression, particularly inducing the proliferation of the so-called T-suppressor 3 effector cells.

Another skin cell group with a dendritic morphology can be identified by the presence on its surface of the Thy-1 molecule (Bergstresser et al., 1983; Tschachler et

al., 1983). Some investigators believe that the Thy-1 positive dendritic epidermal cells are immature T-cells, thus emphasizing the importance of the epidermis as a site for extrathymic T-cell differentiation (Stingl et al., 1987). Others propose that Thy-1-positive dendritic epidermal cells are related to natural killer (NK) cells (Caughman et al., 1986). Sullivan et al. (1986) have recently shown that hapten-coupled Thy-1-positive dendritic epidermal cells, when injected intravenously, cause hapten-specific unresponsiveness to subsequent epicutaneous challenge with contact sensitizers.

The Granstein cell and the Thy-1-positive dendritic epidermal cell are two distinct cell groups involved in down-regulatory immune processes, unlike LC which are associated with the up-regulatory circuit. The participation of these new cell types in different pathological conditions has still to be defined.

## *Langerhans cells and infectious diseases*

### *1. Delayed-type hypersensitivity and Langerhans cells*

Recent evidence has shown that the delayed-type hypersensitivity (DTH) response is the result of a sequence of cell interactions rather than a T-cell-mediated event. Most cell types involved in SIS participate in the DTH response, but its main features are LC hyperplasia, Ia-positive keratinocytes, epidermal T-cell accumulation, and a high T-helper-inducer/T-suppressor-cytotoxic CD4/CD8 ratio, with elevated numbers of IL-2-positive T-lymphocytes within the infiltrates (Poulter et al., 1982; Scheynius et al., 1983; Fullmer et al., 1984).

The lack of LC in the cornea has permitted its use as a model to study the participation of these cells in DTH response. Central corneal allografts fail to elicit graft rejection across a MHC II barrier (Streilein et al., 1979). Similarly, central corneal allografts fail to induce a DTH response in allogeneic hosts (Peeler et al., 1985). The latter can be reconstituted after the addition in the graft of donor-derived LC (Peeler and Niederkorn, 1986). Moreover, the epicutaneous application of 2, 4-dinitro-1-fluorobenzene to LC-depleted skin has led to the development of specific immunological tolerance (Toews et al., 1980).

All these findings indicate that LC are required for the induction of DTH responsiveness to various antigens.

In mammals, a considerable number of chronic diseases which manifest DTH are caused by infectious agents such as viruses, mycobacteria, protozoa, and fungi. In all these diseases the association between DTH and protective immunity, and in consequence the participation of LC, have yet to be established.

### *2. Langerhans cells and viral infections*

Cell-mediated immunity plays an important role in resistance to viruses which spread in a cell-to-cell fashion such as herpes, poxvirus, papilloma and HIV (Haftek, 1988).

### Herpes simplex virus type 1 (HSV-1) infection

Sprecher and Becker (1986) demonstrated an increase in LC density after infection of the footpad skin with a pathogenic strain of HSV-1. They also showed that a depletion of LC in the footpad skin produced an enhancement of the virulence in pathogenic and non-pathogenic strains. Further work using steroids to deplete epidermal LC showed that HSV-1 virulence in the murine model depended on the pathogenicity of the virus strain, genetic strain and age of mice, and LC density (Sprecher and Becker, 1987).

### Human papilloma virus (HPV) infection

HPV induces epithelial proliferation of the skin and mucosa, causing various types of disorders which in general are benign although some may progress to squamous cell carcinoma (Gissman, 1984). In HPV infection, the density of LC is always decreased in the epidermal lesions, suggesting that this may be the result of virus-specific cytopathic effect (Chardonnet et al., 1986). The results show correlation between the density reduction in LC and the extent of the cytopathic changes independent of the virus types.

### Human immunodeficiency virus (HIV) infection

The expression of CD4 molecules on the surface of LC implies that they may be possible targets of HIV infection. Belsito et al. demonstrated that AIDS/ARC patients have decreased numbers of epidermal LC (Belsito et al., 1984). This decrease in LC density in AIDS patients could be correlated with the clinical stage and the absolute numbers of peripheral blood T-helper cells (Dréno et al., 1988). Tschachler et al. (1987a) were the first to demonstrate cytopathic changes and HIV-like particles in most LC from AIDS patients. In the same study, LC were the only epidermal cells to react with a monoclonal antibody specific to HIV core protein p17. Recent evidence suggests that LC are the primary targets for HIV infection and an important virus reservoir (Niedecken et al., 1987; Tschachler et al., 1987b).

### 3. Langerhans cells in mycobacterial and parasitic diseases. Langerhans cells in leprosy

The clinical-pathological spectrum of leprosy in its diverse forms is the expression of the immunological response of the human host to infection by *Mycobacterium leprae* (Convit et al., 1983). The two polar forms of the spectrum are lepromatous leprosy (LL), in which patients do not develop cell-mediated response to *M. leprae* antigens, and tuberculoid leprosy (TL), in which patients do develop cell-mediated immune response to the bacillus (Bullock and Fasal, 1971; Convit et al., 1983).

Epidermal LC appeared to be increased in TL (Modlin et al., 1983a,b; Mathur et al., 1984) (Fig. 2). In dermis, CD1a-positive dendritic cells are usually located at the borders of the granulomas, especially in the

papillary dermis. In erythema nodosum leprosum, a reactional state, the density of LC is found within normal skin values; however, most LC are located in the periphery of the granulomas as in TL. Most studies have shown that the density of LC in LL and borderline lepromatous specimens varies considerably (Modlin et al., 1983b; Liu et al., 1984; Alvarenga et al., 1985). Many cases of LL have decreased numbers of LC with some evidence of morphological cell damage, maybe as the result of LC being the targets of *M. leprae*.



Fig. 2. Numerous epidermal Langerhans cells in a lesion of tuberculoid leprosy. Avidin-biotin immunoperoxidase using an anti-CD1a. Bar = 20  $\mu$ m.

Dugan et al. (1985) carried out an *in situ* leukocyte characterization of the Mitsuda reaction, the intradermal skin test for assessing the immunological status and the prognosis of leprosy patients. They found a LC hyperplasia which compromises 5% of the total epidermal cell count in both tuberculoid and reversal reaction lesions. CD1a-positive cells were also seen within the dermis in areas of the granulomatous response. Besides the LC hyperplasia, other features include a selective accumulation of T-cells in the epidermis, and a high T-helper-inducer/T-suppressor-cytotoxic CD4/CD8 ratio. These results are similar to those found for tuberculin reactions, the classical DTH response (Poulter et al., 1982; Scheynius et al., 1983; Modlin et al., 1983b; Fullmer et al., 1984).

Recently, Gross et al. (1988) have studied the granulomatous response produced after the inoculation of a mixture of *M. leprae* and BCG in LL patients. They found an increase in the numbers of LC CD1a-positive in the epidermis. In dermis, these cells were mainly localized in the mantle surrounding the granuloma, as described for TL and tuberculin DTH responses (Fig. 3). These findings confirm Convit's observations that the injection of heat-killed *M. leprae* and BCG in LL patients induced an immune granuloma with elimination of both mycobacteria (Convit et al., 1972). These results provided the experimental basis for the use of the mixture of two mycobacteria, one providing the necessary specific antigens and the other triggering macrophage digestion, in studies of immunotherapy and immunoprophylaxis in leprosy (Convit et al., 1979, 1982).

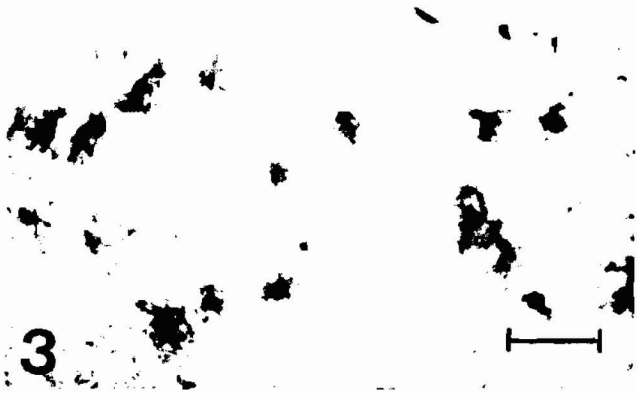

Fig. 3. Langerhans cells (CD1a-positive) distributed around the granulomas of a tuberculoid leprosy patient. Bar = 20  $\mu$ m.

#### American cutaneous leishmaniasis

Cutaneous leishmaniasis results from infection by *Leishmania* species, which are obligatory intracellular parasites of macrophages and monocytes. The parasite is transmitted by *Phlebotomus* sandflies. The sandfly bites are superficial and it is likely that the first targets of *Leishmania* are the LC. The first evidence that LC can be infected by *Leishmania* has recently been shown *in vitro*. (Dompmartin et al., 1988).

Based on these findings, cutaneous leishmaniasis constitutes an excellent model to study the involvement of LC in an infectious disease. American cutaneous leishmaniasis is characterized by a spectrum of host response similar to the one described for leprosy (Convit, 1974). Localized cutaneous leishmaniasis (LCL) is characterized by limited and ulcerated skin lesions which either heal spontaneously or after treatment with pentavalent antimonial salts. In contrast, diffuse cutaneous leishmaniasis (DCL) occurs very rarely and is characterized by the presence of progressive nonulcerated nodules, rich in parasites, which are resistant to treatment (Convit et al., 1972).

Modlin et al. (1985) have shown an increase in the number of epidermal LC, and numerous large CD1a-positive cells in the dermis of LCL lesions. The density of LC in DCL was higher than in normal skin but lower than LCL values (Tapia et al., 1988).

The murine models of cutaneous leishmaniasis have been widely used, since they are very useful in understanding many of the immunoregulatory mechanisms associated with the disease. Depending on the *Leishmania* strain, inoculum size and mouse strain, it has been possible to reproduce the distinct clinical forms observed in human beings. Thus, BALB/c mice reproduce lesions similar to DCL, C57BL/6 mice are resistant, reproducing LCL-like lesions, and DBA mice can show intermediate forms of the disease (Preston et al., 1972; Howard et al., 1981; Pérez, 1982).

Results in our laboratory using the NLDC-145 antibody have shown differences in the numbers of LC in *L. mexicana amazonensis* infected BALB/c and C57BL/6 mice (Tapia et al., 1988). Normal density values for BALB/c mice are

1400 LC/mm<sup>2</sup>, whereas C57BL/6 have about 500 LC/mm<sup>2</sup>, values which are similar to those found in normal human epidermis. The high density of LC in BALB/c mice may contribute to the failure to eliminate the parasite, probably due to an excess of possible target cells or to a hyperfunction of the LC. This study showed an exponential increase of LC during the fifteenth week, and a 40% decrease during the sixteenth week of infection. Susceptible *Leishmania*-infected BALB/c mice also showed an increase in the numbers of epidermal LC (Fig. 4) starting with values similar to those found in normal mice (1300 LC/mm<sup>2</sup>), a decrease during the first week (903 LC/mm<sup>2</sup>) and peak value (2054 LC/mm<sup>2</sup>) during the fourth week. An important observation in dermis of infected C57BL/6 mice is the number of NLDC-145 positive cells in close contact with T-helper L3T4 (Ly4,




Fig. 4. Langerhans cells characterization in separated epidermis of BALB/c mice (9 weeks post-infection). A) normal footpad; B) *Leishmania* inoculated footpad. Avidin-biotin immunoperoxidase using anti-NLDC-145. Bar = 10  $\mu$ m.

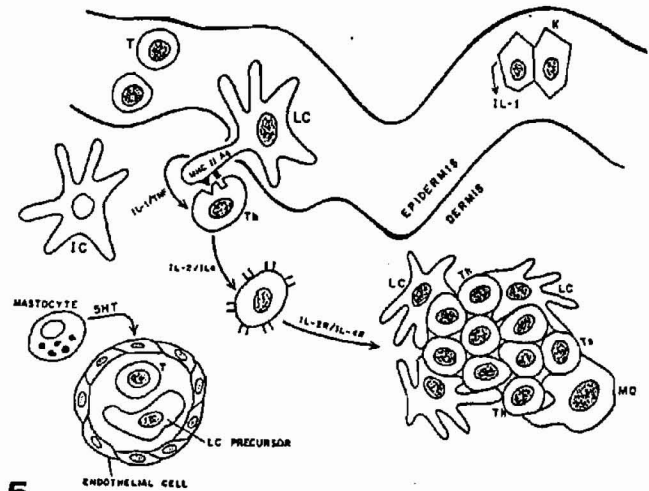
CD4)-positive cells. This type of association may be necessary for lymphokine release, since, as has been described for tuberculoid leprosy, these T-helper cells are also Interleukin-2-positive cells (Modlin et al., 1984). This study shows an association between epidermal LC and the leishmanial infection in murine cutaneous leishmaniasis. This association was made evident through changes in LC density observed during the course of infection. The relevance of these results is being evaluated in our laboratory.

### Langerhans cells and their ultimate role in the immune response

When an infectious agent invades a particular site, polymorphonuclear leukocytes or granulocytes leave the circulating blood and adhere to endothelial cells of the blood vessels. The endothelial cells separate with the help of vasodilator substances, such as serotonin, produced by mast cells, or regulatory peptides such as vasoactive intestinal polypeptide produced by cutaneous nerves or lymphocytes (O'Shaughnessy et al., 1981; O'Dorisio et al., 1985). This vasodilation allows the granulocytes to pass into the infected area where they ingest and destroy the pathogens. Next, antigen-presenting cells, such as LC and macrophages, appear as the predominant cell type, phagociting and destroying the foreign agent.

In the skin, the LC processes the antigen and presents it on its surface in conjunction with MHC class II molecules to a T cell, which in most of the cases is a T-helper cell in capable of producing IL-2 (Th1 cell) or IL-4 (Th2 cell). The cellular association induces the LC to produce and express in its membrane IL-1, and possibly, other monokines such as tumor necrosis factor (TNF). Keratinocytes may also produce IL-1 and function as accessory cells (Gahring et al., 1985). This event, in association with antigen stimulation, induces the release of IL-2 or IL-4 and the expression of IL-2 or IL-4 receptors, driving antigen-activated T-cells into proliferation (Fig. 5). Th1 cells mediate DTH reaction whereas Th2 mediate immediate hypersensitivity responses (Mosmann and Coffman, 1987). The T-cell proliferation leads to the formation of a granuloma, which could be of various types: a lympho-histiocytic infiltrate or tuberculin-type reaction composed generally of lymphocytes and monocytes, a tuberculoid granuloma composed of lymphocytes, differentiated macrophages, epithelioid cells and multinucleated giant cells, and macrophagic granulomas composed of undifferentiated macrophages and very few lymphocytes. The latter is the result of the presence of persistent agents within the macrophages, which the cell is unable to destroy. Recent evidence (Modlin et al., 1983a; Gross et al., 1988) has shown that the tuberculoid granuloma is structurally organized with T-suppressor-cytotoxic cells and LC distributed towards the periphery and T-helper-inducer cells distributed throughout the granuloma. T-helper cells are often seen in close association with LC. Macrophagic granulomas formed by undifferentiated cells, in contrast, are more disorganized with no particular cell distribution.

LC are considered terminally differentiated cells, although Schuler and Steinmann (1985) have recently proposed that epidermal LC constitute a pool of immature dendritic cells. They showed that the antigen-presenting capacity of LC is considerably increased upon *in vitro* cultivation, thus suggesting that LC need to leave the epithelial micro-environment in order to mature into functional immunological cells. Some basis for this hypothesis are the findings of Czernielewski et al. (1985, 1987) showing that LC actually divide within the epidermis.



5

**Fig. 5.** Langerhans cell participation during the invasion of an infectious agent: 1. LC precursors leave the circulating blood and migrate to the epidermis. 2. LC capture, process and present antigen to T-cells in association with MHC class II molecules. These events are accompanied by the production of IL-1 and TNF, which may also be produced by keratinocytes. 3. The antigen stimulation induces the release of IL-2 or IL-4 and the expression of their receptors, driving antigen-activated T-cells into proliferation, and the possible formation of a granuloma which will eventually try to eliminate the infectious agent. LC = Langerhans cells, K = keratinocytes, MQ = macrophages, t = T-lymphocyte, Th = T-helper cell, Ts = T-suppressor cell, IL-1 = interleukin-1, IL-2 = interleukin 2, IL-4 = interleukin-4, IL-2R = interleukin-2 receptor, IL-4R = interleukin-4 receptor. IC = indeterminate cell.

Recent investigations by Romani et al. (1989) suggest that LC function involves two sequential events: antigen presentation and a sensitization step in which the LC acquires the capacity to induce a T-cell response. The first event occurs in the epidermis whereas the second may occur as the dendritic cells migrate to the draining lymph node or spleen.

Skin cells with potential accessory function include dermal and epidermal macrophages, Thy-1-positive dendritic epidermal cells, LC, and keratinocytes under certain pathological conditions. If the skin is the largest defensive organ it is understandable why accessory cells are so heterogeneous. Some investigators suggest that macrophages are the true phagocytic cells of the skin, whereas LC are only capable of pynocytosis of degraded antigens, previously processed by macrophages or keratinocytes (Hamilos, 1988).

The significance of the increase of LC in different dermatological disorders has still to be elucidated, but it has been suggested that LC may be involved in the initial skin pathology. This may be the case in leishmaniasis where LC are a potential target for the parasites (DompMartin et al., 1988) or as in pigmentary disorders where LC hyperplasia always precedes the formation of the T-lymphocyte infiltrate (De Panfilis and Rowden, 1985; Gross et al., 1987).

LC are certainly the most important antigen-presenting cells of the skin and their ultimate role has still to be clarified. Further studies should concentrate on the association between LC and other cell types involved in the up-regulatory and down-regulatory circuits.

*Acknowledgements.* We are grateful to Dr Marian Ulrich for reading and commenting on this manuscript, Miss Dilia Hernández for excellent typing skills, Dr Julio Cerda for supplying armadillo tissue and Mr Alfonso Sierra for drawing expertise. We appreciate the effort of Luis Alexander Silva and Edward Rojas in generating some of the material used in the present review. Part of the work presented here has been supported by grants CONICIT S1-1936 and CDCH-UCV M-10-35-1932-88. We dedicate this work to Dr. Imelda Campo-Aasen, a Langerhans cell research pioneer.

## References

- Alvarenga F. de B., Nunes Sarnao E., Figueiredo A. de A., Gattas C.R. and Porto J.A. (1985). Distribution of Langerhans cells in the epidermis of hanseniasis patients. *Med. Cut. Iber. Lat. Am.* 13, 187-191.
- Amiot M., Bernard A., Raynal B., Knapp W., Deschildre C. and Boursnell L. (1986). Heterogeneity of the first cluster of differentiation: characterization and epitopic mapping of three CD1 molecules on normal thymus cells. *J. Immunol.* 136, 1752-1758.
- Auböck J., Romani N., Grubauer G. and Fritsch P. (1986). HLA-DR expression on keratinocytes is a common feature of diseased skin. *Br. J. Dermatol.* 114, 465-472.
- Balfour B.M., Drexhage H.A., Kamperdijk E.W.A. and Hoefsmit E. (1981). Antigen-presenting cells, including Langerhans cells, veiled cells and interdigitating cells. In: *Microenvironments and cell differentiation*. Ciba Foundation Symposium 84, pp 281-298.
- Basset F. and Turiaf J. (1965). Identification par la microscopie électronique de particules de nature probablement virale dans les lésions granulomateuses d'une histiocytose «X» pulmonaire. *C.R. Acad. Sci. (D) (Paris)* 261, 3701-3703.
- Belsito D.V., Sánchez M.R., Baer R.L., Valentine F. and Thorbecke G.J. (1984). Reduced Langerhans cell Ia antigen and ATPase activity in patients with the acquired immunodeficiency syndrome. *N. Engl. J. Med.* 310, 1279-1282.
- Bergstresser P.R., Tigelaar R.E., Dees J.H. and Streilein J.W. (1983). Thy-1 antigen-bearing dendritic cells populate murine epidermis. *J. Invest. Dermatol.* 81, 286-288.
- Berle E.J., Braathen L.R. and Thorsby E. (1982). HLA-D/DR restriction of Langerhans cells dependent antigen activation of T lymphocytes. The same D/DR determinants are restriction elements on monocytes and Langerhans cells. *Scand. J. Immunol.* 16, 549-552.
- Berti E., Cerri A., Tomasini D., Muratori S., Cavicchini S. and Caputo R. (1988). In: *The Langerhans Cells*. Tyhivolet, J. and Schmitt D. (eds). Colloque INSERM/John Libbey Eurotext Ltd. London, pp 119-123.
- Billingham R.S. and Medawar P.B. (1953). A study of the branched cells of the mammalian epidermis with especial references to the fate of their division products. *Philos. Trans. R. Soc. Lond. (Biol.)* 237, 151-171.
- Birbeck M.S.C., Breathnach A.S. and Everall J.D. (1961). An electron-microscopic study of basal melanocyte and high-level clear cell (Langerhans cell) in vitiligo. *J. Invest. Dermatol.* 37, 51-64.
- Bos J.D. and Kapsenberg M.L. (1986). The skin immune system. *Immunol. Today* 7, 235-240.
- Braathen L.R. and Thorsby E. (1980). Studies on human epidermal Langerhans cells. I. Alloactivating and antigen presenting capacity. *Scand. J. Immunol.* 11, 401-408.
- Braathen L.R. and Thorsby E. (1982). Studies on human epidermal Langerhans cells. IV. Hla D restriction of Langerhans cell-dependent antigen activation of T lymphocytes. *Scand. J. Immunol.* 15, 55-61.
- Bullock W.E. and Fasal P. (1971). Studies on immune mechanisms in leprosy. *J. Immunol.* 106, 888-889.
- Campo-Aasen I. and Pearse A.G.E. (1966). Enzimología de la célula de Langerhans. *Med. Cut.* 1, 35-44.
- Caughman S.W., Breathnach S.M., Sharrow S.O., Stephany D.A. and Katz S.I. (1986). Culture and characterization of murine dendritic Thy-1 + epidermal cells. *J. Invest. Dermatol.* 86, 615-624.
- Chardonnet Y., Viac J. and Thivolet J. (1986). Langerhans cells in human warts. *Br. J. Dermatol.* 115, 669-675.
- Cocchia D., Michetti F. and Donato R. (1981). Immunochemical and immunocytochemical localization of S-100 antigen and glycoprotein from rat thymus. *Transplant. Proc.* 11, 1646-1647.
- Convit J., Avila J.L., Gohman M. and Pinarci M.E. (1972). A test for the determination of competency in clearing bacilli in leprosy patients. *Bull. WHO* 46, 821-826.
- Convit J. (1974). Leprosy and leishmaniasis. Similar clinical-immunological-pathological models. *Ethiop. Med.* 12, 187-192.
- Convit J., Aranzazu N., Pinarci M.E. and Ulrich M. (1979). Immunological changes observed in indeterminate and lepromatous patients and Mitsuda negative contacts after the inoculation of a mixture of *Mycobacterium leprae* and BCG. *Clin. Exp. Immunol.* 36, 214-220.
- Convit J., Aranzazu N., Ulrich M., Pinarci M.E., Reyes O. and Alvarado J. (1982). Immunotherapy with a mixture of *Mycobacterium leprae* and BCG in different forms of leprosy and in Mitsuda negative contacts. *Int. J. Lepr.* 50, 415-424.
- Convit J., Aranzazu N., Zúñiga M., Ulrich M., Pinarci M.E., Castellasi Z., Alvarado J. (1983). Immunotherapy and immunoprophylaxis of leprosy. *Lepr. Rev. Special Issue*, 47-60.
- Czernielewski J.M., Schmitt D., Faure M. and Thivolet J. (1983). Functional and phenotypic analysis of isolated human Langerhans cells and indeterminate cells. *Br. J. Dermatol.* 108, 129-138.
- Czernielewski J.M., Vaigot P. and Prunieras M. (1985). Epidermal Langerhans cells - a cycling cell population. *J. Invest. Dermatol.* 84, 424-426.
- Czernielewski J.M. and Demarchez M. (1987). Further evidence for the self-reproducing capacity of Langerhans cells in human skin. *J. Invest. Dermatol.* 88, 17-20.
- De Panfilis G. and Allegra D. (1979). Immunohistochemical study of dermal cell population in psoriatic skin. *Acta Derm. Venerol. Suppl.* 87, 22-26.
- De Panfilis G. and Rowden G. (1985). The possibility of distinguishing a subject of antigen-presenting cells from macrophages by means of anti S-100 protein sera. *Scand. J. Immunol.* 21, 485-488.
- De Panfilis G. (1988). Paul Langerhans' death centennial, July 20, 1988. *J. Invest. Dermatol.* 91, 283.
- De Waal R.M.W., Semeijn J.T., Cornelissen I.M.H. and Ramaekers F.C.S. (1984). Epidermal Langerhans cells contain intermediate

- sized filaments of vimentin type: an immunocytochemical study. *J. Invest. Dermatol.* 82, 602-604.
- Dezutter-Dambuyant C., Schmitt D., Faure M., Cordier G. and Thivolet J. (1984). Detection of OKT6-positive cells in normal peripheral blood (without visible Birbeck granules). *Immunol. Lett.* 8, 121-126.
- Dezutter-Dambuyant C. (1988). Membrane antigens and Birbeck granules of human Langerhans cells. In: «The Langerhans cell». Thivolet J. and Schmitt D. (eds). Colloque INSERM/John Libbey Eurotext Ltd. London. pp 87-97.
- Domp Martin A., Healy A.T., Nacy C.A., Hauser C. and Meltzer M.S. (1988). *Leishmania major* infects and replicates within murine epidermal Langerhans cells. *J. Invest. Dermatol.* 91, 404.
- Dréno B., Milpied B., Bignon J.D., Stalder J.F. and Litoux P. (1988). Prognostic value of Langerhans cells in the epidermis of HIV patients. *Br. J. Dermatol.* 118, 481-486.
- Dugan E., Modlin R.L. and Rea T.H. (1985). An *in situ* immunohistological study of Mitsuda reactions. *Int. J. Lepr.* 53, 404-409.
- Faure M., Frappaz A., Schmitt D., Dezutter-Dambuyant C. and Thivolet J. (1984). Role of HLA-DR bearing Langerhans and epidermal indeterminate cells in the *in vitro* generation of alloreactive cytotoxic T cells in man. *Cell Immunol.* 83, 271-279.
- Ferreira-Márques J. (1951). Systema sensitivum intraepidemicum: Die Langerhanszellen als Rezeptoren des hellen Schmerzes. Doloreceptors. *Arch. Klin. Exp. Dermatol.* 193, 191-250.
- Fithian E., Kung P., Goldstein G., Ruberfeld M., Fenoglio C. and Edelson R. (1981). Reactivity of Langerhans cells with hybridoma antibody. *Proc. Natl. Acad. Sci. U.S.A.* 78, 2541-2544.
- Frelinger J.G., Hood L., Hill S. and Frelinger J.A. (1979). Mouse epidermal Ia molecules have a bone marrow origin. *Nature* 282, 321-323.
- Fullmer M.A., Modlin R.L. and Rea T.H. (1984). The immunohistology of tuberculin reactions. *J. Invest. Dermatol.* 82, 438.
- Gahring L.C., Buckley A. and Daynes R.A. (1985). Presence of epidermal-derived thymocyte activating factor/interleukin-1 in normal human stratum corneum. *J. Clin. Invest.* 76, 1585-1591.
- Giacometti L. and Montagna W. (1967). Langerhans cells: uptake of tritiated thymidine. *Science* 157, 439-440.
- Gissman L. (1984). Langerhans cells in cutaneous pathology. In: The Langerhans cell. Thivolet J. and Schmitt D. (eds). Colloque INSERM/John Libbey Eurotext Ltd. pp 377-385.
- Goordyal P. and Isaacson P.G. (1985). Immunocytochemical characterization of monocyte colonies of human bone marrow: a clue to the origin of Langerhans cells and interdigitating reticulum cells. *J. Pathol.* 146, 189-195.
- Gothelf Y., Sharon N. and Gazit E. (1986). Fractionation of human bone marrow mononuclear cells with Peanut Agglutinin: phenotypic characterization with monoclonal antibodies. *Human Immunol.* 17, 37-44.
- Gothelf Y., Hanau D., Tsur H., Sharon N., Sahar E., Cazenave J.P. and Gazit E. (1988). T6 positive cells in the peripheral blood of burn patients: are they Langerhans cells precursors?. *J. Invest. Dermatol.* 90, 142-148.
- Granstein R.D., Lowy A. and Greene M.I. (1984). Epidermal antigen-presenting cells in activation of suppression: identification of a new functional type of ultraviolet radiation-resistant epidermal cell. *J. Immunol.* 132, 563-565.
- Gross A., Tapia F.J., Mosca W., Pérez R.M., Briceño L., Henriquez J.J. and Convit J. (1987). Mononuclear cell subpopulations and infiltrating lymphocytes in erythema dyschromicum perstans and vitiligo. *Histol. Histopath.* 2, 277-283.
- Gross A., Weiss E., Tapia F.J., Aranzazu N., Gallinoto M.E. and Convit J. (1988). Leukocyte subsets in the granulomatous response produced after inoculation with *Mycobacterium leprae*-BCG in lepromatous patients. *Am. J. Trop. Med. Hyg.* 38, 608-612.
- Gschnait F. and Brenner W. (1979). Kinetics of epidermal Langerhans cells. *J. Invest. Dermatol.* 73, 566-569.
- Haftek M. (1988). Langerhans cells in cutaneous pathology. In: The Langerhans cell. Thivolet J. and Schmitt D. (eds). Colloque INSERM/John Libbey Eurotext Ltd. London. pp 377-385.
- Hamilos D.L. (1988). Immunocompetent dendritic cells. *Year Immunol.* 3, 89-118.
- Hanau D., Fabre M., Schmitt D.A., Garand J.C., Pauly G., Tongio M.M., Mayer S. and Cazenave J.P. (1987). Human epidermal Langerhans cells internalize by receptor-mediated endocytosis T6 (CD1 NA1/3H) surface antigen. Birbeck granules are involved in the intracellular traffic of the T6 antigen. *J. Invest. Dermatol.* 89, 172-177.
- Haynes B.F. (1986). Summary of T-cell studies performed during The Second International Workshop of Leucocyte Differentiation Antigens. In: Leucocyte Typing II. Vol. 1. Human T lymphocytes. Reinherz E.L., Haynes, B.F., Nadler L.M. and Bernstein, I.D. Springer-Verlag. Berlin. pp 3-30.
- Howard J.C., Hale C. and Liew F.Y. (1981). Immunological regulation of experimental cutaneous leishmaniasis. IV. Prophylactic effect of sublethal irradiation as a result of abrogation of suppressor T cell generation in mice genetically susceptible to *Leishmania tropica*. *J. Exp. Med.* 153, 557-568.
- Juhlin L. and Shelley W.B. (1977). New staining techniques for the Langerhans cell. *Acta Derm. Venerol.* 57, 289-296.
- Katz S.I., Tamaki K. and Sachs D.H. (1979). Epidermal Langerhans cells are derived from cells originating in the bone marrow. *Nature* 282, 324-326.
- Klareskog L., Tjernlund U.M., Forsum U. and Peterson P.A. (1977). Epidermal Langerhans cells express Ia antigen. *Nature* 268, 284-250.
- Klaus G.G.B., Humphrey J.H., Kunkl A. and Dongworth D.W. (1980). The follicular dendritic cell: its role in antigen presentation in the generation of immunological memory. *Immunol. Rev.* 53, 3-28.
- Kraal G., Breel M., Janse M. and Bruin G. (1986). Langerhans cells, veiled cells and interdigitating cells in the mouse recognized by a monoclonal antibody. *J. Exp. Med.* 163, 981-997.
- Langerhans P. (1868). Über die Nerven der menschlichen Haut. *Virchows Arch.* 44, 325-337.
- Liu J., Shi Y., Kong Q., Yang L., Li W. and Ye G. (1984). Observations on Langerhans cells in leprosy using monoclonal antibody OKT6. *Int. J. Lepr.* 52, 524-526.
- Löning T., Caselitz J., Seifert G., Weber K. and Osborn M. (1982). Identification of Langerhans cells. Simultaneous use of sera to intermediate filaments, T6 and HLA-DR antigens on oral mucosa. *Virchows Arch (A)* 398, 119-128.
- Martin L.H., Calabi F. and Milstein C. (1986). Isolation of CD1 genes: a family of major histocompatibility complex-related



- differentiation antigens. Proc. Natl. Acad. Sci. USA. 83, 9154-9158.
- Martin L.H., Calabi F., Lefebvre F.A., Bisland A.G. and Milstein C. (1987). Structure and expression of the human thymocyte antigens CD1a, CD1b, and CD1c. Proc. Natl. Acad. Sci. USA 84, 9189-9193.
- Mackenzie I.C. (1975). Labelling of murine epidermal Langerhans cells with <sup>3</sup>H-thymidine. Am. J. Anat. 144, 127-136.
- Mathur N.K., Mangal H.N., Mathur D.C. and Agrawal U.S. (1984). Epidermal Langerhans cells in subtypes of leprosy. Int. J. Lepr. 52, 92-93.
- McMichael A.J., Pilch J.R., Galfre G., Mason D.Y., Fabre J.W. and Milstein C. (1979). A human thymocyte antigen defined by a hybrid myeloma monoclonal antibody. Eur. J. Immunol. 9, 205-210.
- Miyauchi S. and Hashimoto K. (1989). Mitotic activities of normal epidermal Langerhans cells. J. Invest. Dermatol. 92, 120-121.
- Modlin R.L., Hofman F.M., Taylor C.R. and Rea T.H. (1983a). T lymphocyte subsets in the skin lesions of patients with leprosy. J. Am. Acad. Dermatol. 8, 182-189.
- Modlin R.L., Gebhard J.F., Taylor C.R. and Rea T.H. (1983b). *In situ* characterization of T lymphocyte subsets in the reactional states of leprosy. Clin. Exp. Immunol. 53, 17-24.
- Modlin R.L., Hofman F.M., Horwitz D.A., Husmann L.A., Gillis S., Taylor C.R. and Rea T.H. (1984). *In situ* identification of cells in human leprosy granulomas with monoclonal antibodies to interleukin-2 and its receptor. J. Immunol. 132, 3085-3090.
- Modlin R.L., Tapia F.J., Bloom B.R., Gallinoto M.E., Castés M., Rondón A.J., Rea T.H. and Convit J. (1985). *In situ* characterization of the cellular immune response in American cutaneous leishmaniasis. Clin. Exp. Immunol. 60, 241-248.
- Mosmann T.R. and Coffman R.L. (1987). Two types of mouse helper T-cell clone. Implications for immune regulation. Immunol. Today 8, 223-227.
- Murphy G.F. (1985). Cell membrane glycoproteins and Langerhans cells. Human Pathol. 16, 103-112.
- Nakajima T., Watanabe S., Sato Y., Shimosato Y., Motoi M. and Lennert K. (1982). S-100 protein in Langerhans cells, interdigitating reticulum cells and histiocytosis X cells. Gann. 73, 429-432.
- Niebauer G. (1968). Dendritic cells of human skin. In: Experimental Biology and Medicine. Vol 2, Hagen E., Weschsler W. and Zilliken F. (eds).
- Niedecken H., Lutz G., Bauer R. and Kreysel H.W. (1987). Langerhans cells as primary target and vehicle for transmission of HIV. Lancet 2, 519-520.
- Olive D., Dubreuil P. and Mawas C. (1984). Two distinct TL-like molecular subsets defined by monoclonal antibodies on the surface of human thymocytes with different expression on leukemia lines. Immunogenetics 20, 253-264.
- O'Dorisio M.S., Wood C.L. and O'Dorisio T.M. (1985). Vasoactive intestinal polypeptide and neuropeptide modulation of the immune response. J. Immunol. 135, 7925-7965.
- O'Shaughnessy D.J., McGregor G.P., Mina S., Ghatei M.A., Gu J., Polak J.M. and Bloom S.R. (1981). Regulatory peptides in the skin. Soc. Endocrinol. 164th Meeting, p 26.
- Peeler J.S., Niederkorn J.Y. and Matoba A. (1985). Corneal allografts induced cytotoxic T cell but not delayed hypersensitivity responses in mice. Invest. Ophthalmol. Vis. Sci. 23, 489.
- Peeler J.S. and Niederkorn J.Y. (1986). Antigen presentation by Langerhans cells *in vivo*: donor-derived Ia+ Langerhans cells are required for induction of delayed-type hypersensitivity but not for cytotoxic T lymphocyte responses to allo-antigens. J. Immunol. 136, 4362-4371.
- Pelletier M., Perreault C., Landry D., David M. and Montplaisir S. (1984). Ontogeny of human epidermal Langerhans cells. Transplantation 38, 544-546.
- Pérez H.A. (1982). Inmunología de la leishmaniasis cutánea experimental. Adel. Microbiol. Enf. Infec. 1, 103-110.
- Poulter L.W., Seymour G.J., Duke O., Janossy G. and Panayi G. (1982). Immunohistological analysis of delayed-type hypersensitivity in man. Cell. Immunol. 74, 358-369.
- Preston P.M., Carter R.L., Leuchars E., Davies A.J.S. and Dumonde D.C. (1972). Experimental cutaneous leishmaniasis. III Effects of thymectomy on the course of infectious of CBA mice with *Leishmania tropica*. Clin. Exp. Immunol. 10, 337-357.
- Rodríguez E.M. and Caorsi I. (1978). A second look at the ultrastructure of the Langerhans cell of the human epidermis. J. Ultrastruct. Res. 65, 279-295.
- Romani N., Koide S., Crowley M., Witner-Pack M., Livingstone A.M., Fathman C.G., Inaba K. and Steinman R.M. (1989). Presentation of exogenous protein antigens by dendritic cells to T cell clones. Intact Protein is presented best in immature epidermal Langerhans cells. J. Exp. Med. 169, 1169-1178.
- Rowden G., Lewis M.G. and Sullivan A.K. (1977). Ia antigen expression on human epidermal Langerhans cells. Nature 268, 247-248.
- Sauder D.N., Dinarello C.A. and Morhenn V.B. (1984). Langerhans cell production of interleukin 1. J. Invest. Dermatol. 82, 605-607.
- Scheynius A., Klareskog L. and Forsum U. (1983). *In situ* identification of T lymphocyte subsets and HLA-DR expressing cells in the human skin tuberculin reactions. Clin. Exp. Immunol. 49, 325-330.
- Schmitt D., Zambrano G., Staquet M.J., Dezutter-Dambuyant C., Ohrt C., Brochier J. and Thivolet J. (1987). Antigenic thymus-epidermis relationships. Reactivity of a panel of anti-thymic cell monoclonal antibodies on human keratinocytes and Langerhans cells. Dermatologia 175, 109-120.
- Schuler G. and Steinman R.M. (1985). Murine epidermal Langerhans cells mature into potent immunostimulatory dendritic cells *in vitro*. J. Exp. Med. 161, 526-583.
- Silberberg I. (1973). Apposition of mononuclear cells to Langerhans cells in contact allergic reactions. An ultrastructural study. Acta Derm. Venerol. 53, 1-12.
- Silberberg-Sinakin I., Thorbecke G.J., Baer R.L., Rosenthal S.A. and Bezerowsky V. (1976). Antigen-bearing Langerhans cells in skin, dermal lymphatics and in lymph nodes. Cell Immunol. 25, 137-151.
- Small T.N., Knowles R.W., Keever C., Kernan N.A., Collins N., O'Reilly R.J., Dupont B. and Flomenberg N. (1987). Expression of the M241 (CD1) antigen on B lymphocytes. In: Leucocyte typing 3. McMichael A.J., Beverley P.C.L., Gobbold S., Crumpton M.J., Gilks W., Gotch F.M., Hogg N., Horton M., Ling N., MacLennan I.C.M., Mason D.Y., Milstein C., Spiegelhalter D. and Waldman H. (eds). Oxford University Press. Oxford.
- Sprecher E. and Becker Y. (1986). Skin Langerhans cells play an essential role in the defense against HSV-1 infection. Arch. Virol. 91, 341-349.

- Sprecher E. and Becker Y. (1987). Herpes simplex virus type 1 pathogenicity in footpad and ear skin of mice depends on Langerhans cells density mouse genetics, and virus strain. *J. Virol.* 61, 2515-2522.
- Stingl G., Wolff-Schreiner E.C., Pichler W.J., Gschnait F., Knapp E. and Wolff K. (1977). Epidermal Langerhans cells bear Fc and C3 receptors. *Nature* 268, 245-246.
- Stingl G., Katz S.I., Clement L., Green I. and Shevach E.M. (1978). Immunologic functions of Ia bearing epidermal Langerhans cells. *J. Immunol.* 121, 2005-2013.
- Stingl G., Gunter K.C., Tschachler R., Yamada H., Lechler R.I., Yokoyama W.M., Steiner G., Germain R.N. and Shevach E.M. (1987). Thy-1 + dendritic epidermal cells belong to the T cell lineage. *Proc. Natl. Acad. Sci. USA* 84, 2430-2434.
- Streilein J.W. (1978). Lymphocyte traffic, T cell malignancies and the skin. *J. Invest. Dermatol.* 71, 167-171.
- Streilein J.W., Toews G.B. and Bergstresser P.R. (1979). Corneal allografts fail to express Ia antigens. *Nature* 282, 326-327.
- Sullivan S., Bergstresser P.R., Tigelaar R.E. and Streilein J.W. (1986). Induction and relation of contact hypersensitivity by resident bone marrow-derived, dendritic, dendritic epidermal cells: Langerhans cells and Thy-1 + epidermal cells. *J. Immunol.* 137, 2460-2467.
- Tapia F.J., Rojas E., Kraal G., Mosca W. and Convit J. (1988). Immunocytochemical analysis of Langerhans cells in murine cutaneous leishmaniasis. In: *The Langerhans cell*. Thivolet J. and Schmitt D. (eds). Colloque INSERM/John Libbey Eurotext Ltd. London. pp 479-490.
- Toews G.B., Bergstresser P.R. and Streilein J.W. (1980). Epidermal Langerhans cells density determines whether contact hypersensitivity or unresponsiveness follows skin painting with DNFB. *J. Immunol.* 124, 445-453.
- Tschachler E., Shuler G., Hutterer J., Leibl H., Wolff K. and Stingl G. (1983). Expression of Thy-1 antigen by murine epidermal cells. *J. Invest. Dermatol.* 81, 282-285.
- Tschachler E., Groh V., Popovic M., Mann D.L., Konrad K., Safai B., Eron L., di Marzo Veronese F., Wolff K. and Stingl G. (1987a). Epidermal Langerhans cells. A target for HTLV-III/LAV infection. *J. Invest. Dermatol.* 88, 233-237.
- Tschachler E., Groh V., Rappersberger K., Gardner S., Popovic M., Schenk P., Konrad K., Mann D.L., Wolff K. and Stingl G. (1987b). Epidermal Langerhans cells: a virus reservoir in HIV infection. *J. Invest. Dermatol.* 88, 522.
- Unanue E.R. (1972). The regulatory role of macrophages in antigenic stimulation. *Adv. Immunol.* 15, 95-165.
- Unanue E.R. (1981). The regulatory role of macrophages in antigenic stimulation. II. Symbiotic relationship between lymphocytes and macrophages. *Adv. Immunol.* 31, 1-136.
- Wolff K. (1972). The Langerhans cell. *Curr. Probl. Dermatol.* 4, 79-145.
- Wood J., O'Mahamy J.B., Palder S.B., Rodrick M.L., D'Eon P. and Mannick J.A. (1984). Circulating T6 antigen positive cells. *J. Invest. Dermatol.* 82, 387-388.