

Inadequate epidermal homing leads to tissue damage in human cutaneous leishmaniasis

Felix J. Tapia, Gisela Cáceres-Dittmar
and Martín A. Sánchez

Leishmaniasis is a model disease for the study of immunoregulatory mechanisms associated with host resistance and susceptibility. In this article, Felix Tapia and colleagues propose that defects in the signaling properties of the epidermis can result in the generation of either a chronic granulomatous response, which is unable to eliminate the parasite, or a proinflammatory mucocutaneous response and tissue damage.

Leishmaniasis is caused by intracellular protozoan parasites of the genus *Leishmania*. The disease is transmitted to the mammalian host by the bite of female sandflies of the *Phlebotominae* subfamily, resulting in parasite inoculation into the skin epidermis or the upper layer of the dermis. The parasites then either multiply in the skin, causing circumscribed lesions, or disseminate to distal skin, mucocutaneous membranes or visceral lymphoid organs. In the New World, the cutaneous disease is termed American cutaneous leishmaniasis (ACL) and is characterized by a spectrum of clinical, histopathological and immunological manifestations^{1,2}.

Leishmaniasis provides an excellent model to understand the various regulatory mechanisms that mediate host resistance and susceptibility to disease, and has implications for other infectious diseases. This is due both to the existence of experimental models of leishmaniasis in different inbred strains of mice and to the diversity of the immune response to *Leishmania* in humans. The contact between *Leishmania* parasites and the cutaneous immunocompetent cells promotes an immune response that is mainly directed towards the elimination of the parasite. However, under certain conditions, the immune response can also be involved in tissue damage. In this article, a model is proposed for tissue destruction in ACL that invokes defects at the epidermal level as a causative factor.

Cutaneous leishmaniasis

The most common form of ACL is termed localized cutaneous leishmaniasis (LCL). In this form of the disease, an adequate cell-mediated immune (CMI) response is mounted and leishmaniasis is restricted to well-defined skin lesions¹⁻³. Histologically, LCL granulomas are composed of a prominent infiltration of lymphocytes, variable numbers of epithelioid (epithelial-like) cells and few parasites. Ulcerated lesions show variable degrees of epidermal-cell hyperplasia, which depend on the time of evolution and type of lesion produced³. By contrast, diffuse cutaneous leishmaniasis (DCL) occurs infrequently and is characterized by a selective anergy in CMI, which results in extensive involvement of the skin, nasobucopharyngeal mucosal tissue and some lymph nodes¹⁻⁵. DCL lesions contain numerous undifferentiated macrophages laden with parasites, and have few lymphocytes and plasma cells³. Indeed, *Leishmania* parasites have been demonstrated in the epidermis of 20–40% of lesions in patients with a high burden of parasites⁶. A third form, mucocutaneous leishmaniasis (MCL), is characterized by exacerbated CMI and destructive lesions of the oral and nasopharyngeal cavities, which may appear long after the primary skin lesions have healed^{2,4,5}. The MCL granuloma is a mixture of lymphocytes and macrophages, with few parasites and moderate epidermal changes⁷.

The skin immune response

The skin is an important part of the immune system and is the site of complex humoral and cellular responses. Indeed, it has been regarded as a self-supporting immunological organ comprising: immunocompetent cells (including epidermal Langerhans cells, keratinocytes and skin T cells); the dermal perivascular unit (including endothelial cells, pericytes of the vasculature, T cells, mast cells and dermal dendrocytes); and interacting cytokines and chemokines^{8,9}.

The two major types of antigen-presenting cells (APCs) located within the epidermis are Langerhans cells and keratinocytes. Langerhans cells are members of the dendritic-cell family, and are omnipresent cutaneous APCs. By contrast, keratinocytes only become active immunocompetent cells after a cutaneous stimulus^{10,11}. Both cell types participate in the generation of the inflammatory process by expressing major histocompatibility complex (MHC) class II antigens and adhesion molecules, which are necessary for the migration and retention of inflammatory cells¹⁰⁻¹². Langerhans cells and keratinocytes also produce monokines, which may help to induce the migration of epidermotropic T cells. These include interleukin 1 (IL-1), IL-6, IL-8, granulocyte-macrophage colony-stimulating factor (GM-CSF), tumor necrosis factor α (TNF- α) and TNF- β (Ref. 12). Furthermore, keratinocytes may present antigen in a MHC class II-restricted manner to T cells, thereby increasing their contribution to local CMI (Ref. 13). Thus, the epidermis appears to play an important role in the initiation of the inflammatory process^{12,14}.

The immunoregulatory processes of the skin have been described as occurring in three phases: recruitment, retention/proliferation and recirculation¹². The recruitment phase involves the extravasation of leukocytes through the perivascular unit, and the subsequent movement of these cells towards the epidermis. The retention/proliferation phase comprises the interaction between Langerhans cells, keratinocytes, epidermotropic T cells and cytokines, and the subsequent proliferation of T cells and formation of a dermal infiltrate or granuloma. The recirculation phase is activated after the elimination of the cutaneous insult, and involves the downregulation of accessory signals provided by Langerhans cells and keratinocytes. The immunoregulatory process can be affected by factors that include the nature of the antigen, epidermal APCs, effector T cells and cytokines.

The dermal infiltrate or granuloma can have a particular microanatomic configuration, with CD8⁺ cytotoxic T cells (CTL) and CD1a⁺ Langerhans cells arranged in the mantle surrounding the infiltrate, and CD4⁺ T-helper (Th) cells and epithelioid cells located randomly. This organization has been observed in delayed-type hypersensitivity (DTH) responses and tuberculoid-type granulomas¹⁵⁻¹⁷. In addition, the immune response is either Th1 or Th2 type, depending on the cytokines that are secreted¹⁸. Th1 cells secrete IL-2, TNF- β and interferon γ (IFN- γ), and mediate CMI responses, including DTH and macrophage activation. Th2 cells secrete IL-4, IL-5, IL-6 and IL-10, and assist in antibody production for humoral

immunity^{18,19}. A third phenotype, designated Th0, produces IL-2, IL-3, IL-4, IL-5, IL-10, GM-CSF and IFN- γ , and is often observed after short-term stimulation^{19,20}. Other phenotypes include naive and memory T cells, which produce IL-2 (Ref. 18).

The development of the cutaneous immune response can also be influenced by mast cells, which are capable of producing TNF- α after stimulation²¹. Furthermore, the perivascular unit may contribute to the process of leukocyte extravasation by secreting neuropeptides and amines that induce vasodilation. Similarly, keratinocyte-derived chemokines promote T-cell homing to the epidermis, such as IL-1, leukotriene B₄, transforming growth factor β (TGF- β), substance P and IFN- γ -induced protein (IP-10) (Ref. 12). In addition, the interaction between inflammatory cells and components of the extracellular matrix (e.g. laminin, fibronectin and collagen) may induce cytokine production²² and influence T-cell migration and differentiation²³.

Immunological disease in ACL

The skin immune system participates in the immunoregulatory mechanisms that are involved in human and experimental ACL (Fig. 1; Ref. 24). The cascade of events that occurs during this inflammatory reaction vary between the different clinical forms of leishmaniasis. Recently, studies in the mouse model for leishmaniasis identified epidermal Langerhans cells as playing a key immunoregulatory role in the disease, and showed that these cells are powerful stimulators of parasite-specific T-cell proliferation²⁵.

LCL: effective control of infection

The epidermal lesions of patients with LCL contain many components that are associated with active inflammation. These include: appropriate numbers of CD1a⁺ Langerhans cells^{24,26,27}; marked expression of MHC class II by keratinocytes; and the presence of groups of keratinocytes that express intercellular adhesion molecule 1 (ICAM-1) (Fig. 2; Refs 24,26-28). Furthermore, a subgroup of epidermal Langerhans cells within the lesions express HB15 (Ref. 29), a newly identified member of the immunoglobulin superfamily that is also present on activated lymphocytes³⁰. The distribution of the ICAM-1 molecule in LCL epidermis is similar to that observed in a number of other skin disorders, and is associated with IFN- γ production and selective migration of epidermotropic T cells³¹. Furthermore, mRNA transcripts for IFN- γ , IL-1 β , TNF- α , TNF- β and IL-8 (but not IL-6) can be detected in LCL epidermal sheets using the reverse transcriptase polymerase chain reaction (RT-PCR) (Ref. 24). By contrast, IL-6 can be detected in the entire LCL lesion using the same procedure³². LCL granulomas show a mixture of Th1 and Th0 responses, with a predominance of Th1 cytokines (more IFN- γ than IL-4, and low levels of IL-5 and IL-10) (Ref. 32). The levels of various T-cell subsets within the LCL epidermis (Table 1) indicates that effector mechanisms, such as macrophage activation and the lysis of infected cells, are involved in the control of disease³³.

The presence of parasites in the skin induces the local production of IFN- γ within LCL lesions. This,

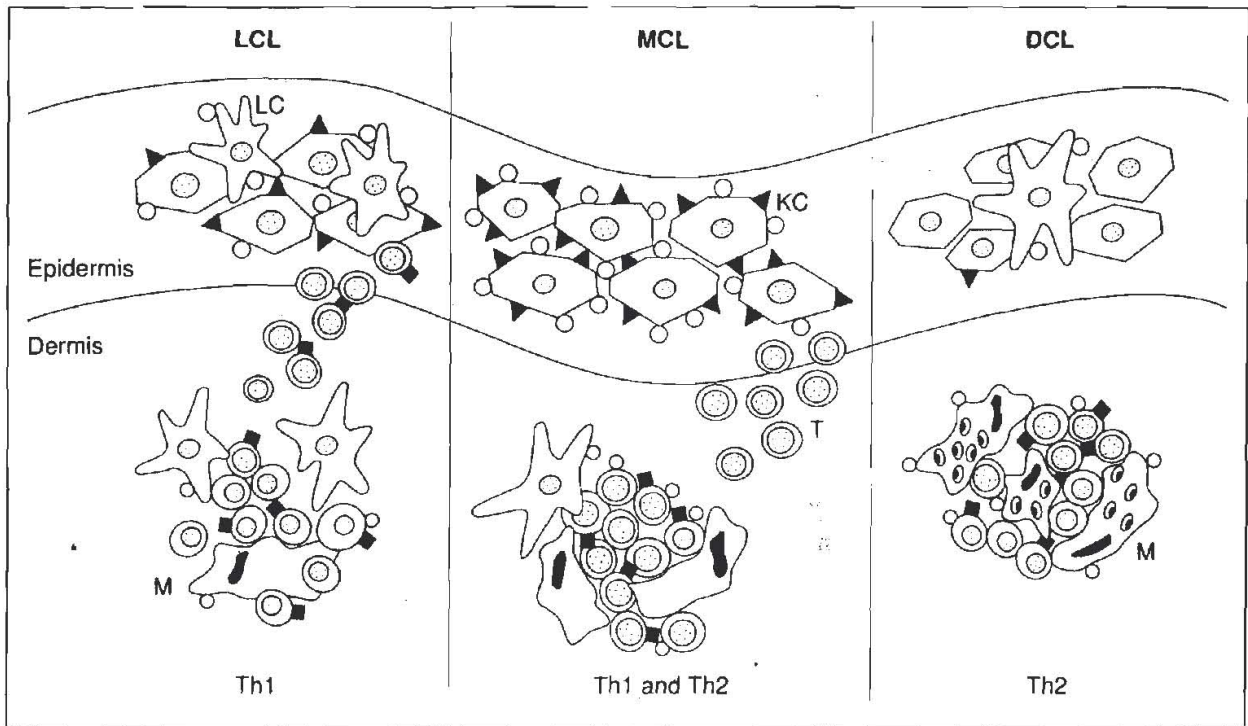


Fig. 1. Immune response in American cutaneous leishmaniasis. Localized cutaneous leishmaniasis (LCL) has most of the components associated with an active inflammatory process: abundant Langerhans cells (LCs); keratinocytes (KCs) expressing intercellular adhesion molecule 1 (ICAM-1) (solid triangle) and major histocompatibility complex (MHC) class II (HLA-DR) (empty circle); a selective accumulation of epidermotropic T cells (T) expressing leukocyte function-associated antigen 1 (LFA-1) (solid rectangle); and the generation of a Th1 response. Mucocutaneous leishmaniasis (MCL) is characterized by exacerbated expression of ICAM-1 and HLA-DR by KCs, a lack of epithelial LCs, epithelial T-cell traffic, and a Th1/Th2 granuloma. In diffuse cutaneous leishmaniasis (DCL), KCs do not express ICAM-1 or HLA-DR, there are few LCs and a defective production of monokines. The DCL granuloma exhibits a Th2 response, with many parasite-loaded HLA-DR⁺ macrophages (M).

and other cytokines such as TNF- β , could lead to the expression of ICAM-1 and MHC HLA-DR on keratinocytes, and promote the migration of epidermotropic T cells. Langerhans cells are potent stimulators of T cells that are specific for *Leishmania*³⁴, and can thereby promote an effective Th1 response against the parasite. Once the parasite is eliminated, or masked from recognition by the host immune system, the epidermal accessory signals are downregulated. This induces healing of the cutaneous immunopathology that has caused the lesion. Indeed, treatment of *Leishmania*-infected mice with ultraviolet light of spectrum B (UVB) alleviates the dermatological manifestation, without reducing the parasite load³⁵.

DCL: APC dysfunction and selective anergy

Epidermal deficiencies of cytokines and cytokine-mediated accessory signals may affect APC function and induce parasite-specific anergy. DCL epidermis has few CD1a⁺ and HB15⁺ Langerhans cells^{16,29}, and the keratinocytes fail to express either MHC class II or ICAM-1 (Ref. 27). DCL epidermis also lacks IL-6, and only a few patients express mRNA for IL-1 β and TNF- α (Ref. 32), indicating a possible failure at the level of monokine production by the APC. Indeed, the lack of IL-6 may be the result of the poor expression of IL-1 β and TNF- α , as these cytokines are necessary to induce IL-6 production³⁶. Furthermore, the presence of IFN- γ in the DCL lesions may contribute to the lack of

message for IL-1 β , since IFN- γ is known to downregulate IL-1 production³⁷. The DCL granuloma shows a predominantly Th2-mediated response, producing IL-4, IL-5 and IL-10 (Ref. 32), with an unusually high number of naive T cells and no particular microanatomic arrangement (see Table 1 for the relative levels of other T-cell subsets). There is also an apparent defect in the expression of leukocyte function-associated antigen 1 (LFA-1), resulting in a higher number of LFA-1⁺ T cells than observed in LCL lesions²⁹.

The disparity in the levels of CD1a⁺ and HB15⁺ cells between LCL and DCL lesions may be related to cell triggering, since HB15 expression has been associated with antigen presentation and the cellular interactions that follow lymphocyte activation³⁰. Indeed, the HB15 molecule may distinguish a subset of primed CD1a⁺ Langerhans cells that are responsible for presenting antigen to memory T cells. Thus, LCL lesions possess many of the accessory signals necessary to promote an effective immune response against the *Leishmania* parasite, whereas DCL lesions manifest an impaired epidermal function.

Certain risk factors may make individuals susceptible to DCL, such as the genetic background of the host³⁸, the species of parasite³⁹ and sensitivity to UVB (Ref. 40). In this situation, the parasite evades the immune response of the host, and the cytokines that are produced cannot activate keratinocytes to express ICAM-1 and MHC class II. In addition, Langerhans

cells are diminished either by a direct effect of the parasites⁴¹ or by a lack of epidermal priming. These events lead to the generation of a Th2 response, creating a state of progressive parasite-specific unresponsiveness and resulting in the paralysis of cutaneous T cells.

MCL: APC dysfunction and exacerbated immune response

The most striking feature of MCL lesions is the absence of CD1a⁺ and HB15⁺ Langerhans cells in the mucosal epithelium^{28,29}. This may reflect the selective migration of antigen-primed Langerhans cells from the epithelium to regional lymph nodes, or may be the result of a direct cytolytic effect of the parasite on these cells during the prolonged course of MCL. The lack of Langerhans cells has also been observed in virus-induced mucosal lesions⁴². In MCL epidermis, MHC class II and ICAM-1 are uniformly expressed, confirming the hypersensitivity state associated with this clinical form of leishmaniasis. Furthermore, the selective accumulation of T cells expressing the $\alpha\beta$ T-cell receptor (TCR) occurs towards the basal layer of the mucosal epithelium²⁴. The MCL granuloma shows a mixture of Th1 and Th2 cytokine patterns, characterized by an abundance of IFN- γ , IL-2, IL-4, IL-5 and IL-10 (Ref. 31). The IL-4 cytokine promotes Th2-cell proliferation⁴³ and secretion of IL-10, which downregulates APC accessory signals and production of Th1 cytokines and, thereby, prevents IFN- γ from being fully effective. The MCL granuloma shows a high ratio of CD4⁺ to CD8⁺ T cells, which is distinguished by the marked accumulation of CD4⁺ T cells in lesions and low numbers in peripheral blood^{4,28} (levels of other T-cell subsets are shown in Table 1). Furthermore, the expression of LFA-1 in MCL lesions is altered such that cells express both α and β subunits in a comparable manner²⁹.

Mucosal tissue can become involved in disease many years after the primary cutaneous lesions have been cured. Indeed, it is possible that individuals with no apparent skin lesions remain cryptically infected with *L. brasiliensis*, the only recognized causative agent of MCL. The parasite and/or immunological memory may be activated either by re-infection, immunosuppression or trauma (the so-called Koebner phenomenon in which traumatized uninvolved skin develops disease), causing a chronic immune response with associated mucosal damage. Another factor that may be involved in activation is the vasodilator peptide Maxadilan^{44,45}, which is present in the saliva of *Lutzomyia longipalpis*. This sandfly is a vector of leishmaniasis and is known to enhance parasite infectivity and induce exacerbation of cutaneous lesions. The Maxadilan peptide inhibits IFN- γ activity and antigen presentation by macrophages⁴⁴. Thus, in a given endemic area, recurring sandfly bites may contribute to the hyperactive state of MCL lesions. Indeed, salivary gland lysates, containing Maxadilan, have been used to develop the first reliable murine model of *L. brasiliensis*⁴⁶.

In MCL lesions, activation of the disease may be associated with the hyperproduction of keratinocyte-derived monokines, such as IL-1 and TNF- α . These

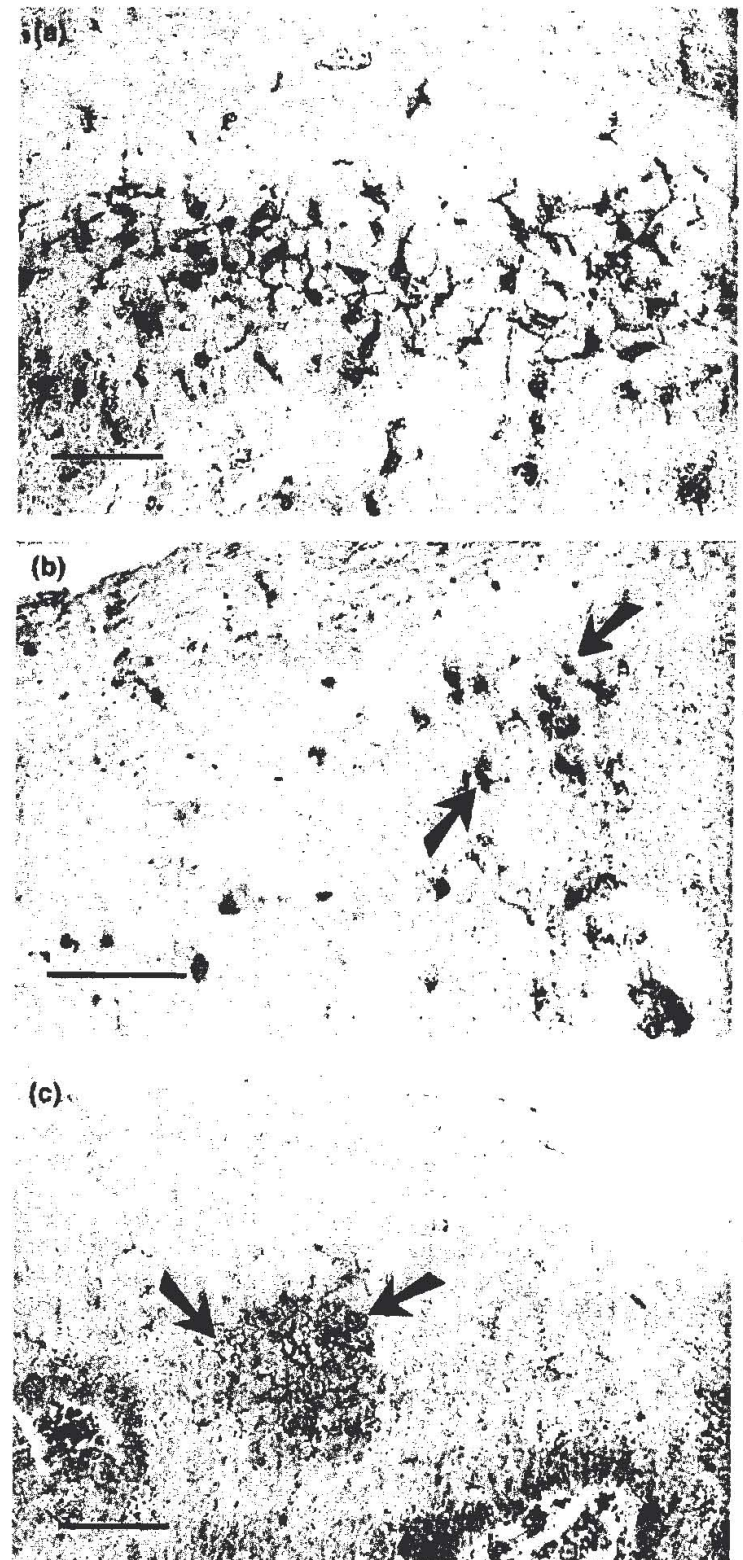


Fig. 2. Epidermal immunocompetent cells in localized cutaneous leishmaniasis. Tissue sections were stained with specific antibodies and avidin-biotin immunoperoxidase, and show: (a) abundant CD1a⁺ Langerhans cells; (b) few HB15⁺ dendritic cells (arrows); and (c) keratinocytes expressing intercellular adhesion molecule 1 (ICAM-1) (arrows). Bars = 20 μ m.

cytokines are capable of upregulating ICAM-1 and MHC class II expression on endothelial and keratinocyte cells, and of initiating T-cell traffic without concomitant antigen presentation. The lack of epithelial Langerhans cells may cause insufficient or inadequate transduction of signals to accomplish the

Table 1. Levels of T-cell subsets found in granulomas of different forms of leishmaniasis^a

Disease	LCL	DCL	MCL
T-cell subsets			
CD4 ⁺ /CD8 ⁺	N	L	H
CD25 ⁺	H	L	L
HB15 ⁺	H	L	L
γδ ⁺	H	L	L
Memory/naive	H	L	H
LFA-1α/LFA-1β	5.7	2.3	1.6

Abbreviations: LCL, localized cutaneous leishmaniasis; DCL, diffuse cutaneous leishmaniasis; MCL, mucocutaneous leishmaniasis; N, normal; H, high; L, low.

^a Data summarized from Refs 16,24,28,29.

effector phase of the immune response. Further release of monokines by keratinocytes could promote a persistent proinflammatory state, with associated tissue damage.

Perspectives

Resistance and susceptibility to leishmanial infection is fostered by early immunological events occurring in the skin and draining lymph nodes. It appears from available evidence that the epidermis is an important homing site for T cells that are specific for *Leishmania*. Accessory signals, such as the expression of ICAM-1 and MHC class II, and the secretion of cytokines, may direct the effector phase of the immune response. Failures at this level will cause an impaired immune response that is not only unable to eliminate the parasite, but which can also result in tissue damage. Indeed, a defect at the level of accessory signals in DCL lesions may account for the selective anergy that is observed in these patients. The macrophage-dense DCL granuloma, which contains many naive T cells, may result from defective signaling by the epidermis and the selective migration of naive and Th2 cells. Similarly, defective signaling at the epithelial level may account for the chronic proinflammatory state that causes tissue damage in MCL. Therefore, it would be of interest to direct future studies towards the analysis of specific factors that may affect the cutaneous immune response in leishmaniasis. Furthermore, novel therapeutic schemes could be devised using the epidermis as a target.

We thank our colleagues from many countries for their donations of antibodies and other reagents, Drs Jacinto Convit and Marian Ulrich for their support, Drs Neil Lynch and Marianella Castés for reading and commenting on the manuscript, and Carmen Fariñas for the drawing. This work was supported by the UNDP/World Bank/WIHO Special Programme for Research and Training in Tropical Diseases and CDCH-Universidad Central de Venezuela Grant 09-35 2379-93 and CONICIT-BID BTS-60.

Felix J. Tapia, Gisela Cáceres-Dittmar and Martín A. Sánchez are in the Laboratory of Molecular Biology, Instituto de Biomedicina, Universidad Central de Venezuela, Apartado 4043, Caracas 1010A, Venezuela.

References

- Convit, J., Pinardi, M.E. and Rondón, A.J. (1972) *Trans. R. Soc. Trop. Med. Hyg.* 66, 603-610
- Convit, J. and Pinardi, M.E. (1974) *Trypanosomiasis and Leishmaniasis with special reference to Chagas' Disease* (Ciba Foundation Symposium 20), pp. 159-166, Elsevier
- Convit, J., Ulrich, M., Fernández, C.T. et al. (1993) *Trans. R. Soc. Trop. Med. Hyg.* 87, 444-448
- Castés, M., Agnelli, A. and Rondón, A.J. (1983) *Clin. Immunol. Immunopathol.* 27, 176-186
- Castés, M., Cabrera, M., Trujillo, D. and Convit, J. (1988) *J. Clin. Microbiol.* 26, 1207-1213
- Azadeh, B., Samad, A. and Ardehali, S. (1985) *Trans. R. Soc. Trop. Med. Hyg.* 79, 631-636
- Magalhaes, A.V., Moraes, M.A.P., Raick, A.N. et al. (1986) *Rev. Inst. Med. Trop. Sao Paulo* 28, 253-262
- Bos, J.D. and Kapsenberg, M.L. (1993) *Immunol. Today* 14, 75-78
- Sontheimer, R.D. (1989) *J. Invest. Dermatol.* 93, 96s-101s
- Breathnach, S.M. and Katz, S.I. (1983) *J. Immunol.* 131, 2741-2745
- Aubock, J., Romani, N., Grauber, G. and Fritsch, P. (1986) *Br. J. Dermatol.* 114, 465-472
- Nickoloff, B.J. (1988) *Arch. Dermatol.* 124, 1835-1843
- Mutis, T., De Bueger, M., Bakker, A. and Ottenhoff, T.H.M. (1993) *Scand. J. Immunol.* 37, 43-51
- Tapia, F.J., Cáceres-Dittmar, G., Acuña, L. and Mosca, W. (1989) *Histol. Histopathology* 4, 499-508
- Modlin, R.L., Hofman, F.M., Meyer, P.R. et al. (1983) *Clin. Exp. Immunol.* 51, 430-438
- Modlin, R.L., Tapia, F.J., Bloom, B.R. et al. (1985) *Clin. Exp. Immunol.* 60, 241-248
- Gross, A., Weiss, E., Tapia, F.J. et al. (1988) *Am. J. Trop. Med. Hyg.* 38, 608-612
- Mosmann, T.R., Cherwinski, H., Bond, M.W., Giedlin, M.A. and Coffman, R.L. (1986) *J. Immunol.* 136, 2348-2357
- Mosmann, T.R. and Moore, K.W. (1991) in *Immunoparasitology Today* (Ash, C. and Gallagher, R.B., eds), pp. A49-A53, Elsevier Trends Journals
- Mosmann, T.R. (1991) *Res. Immunol.* 142, 9-13
- Walsh, L.J., Trinchieri, G., Waldorf, H.A., Whitaker, D. and Murphy, G.F. (1991) *Proc. Natl Acad. Sci. USA* 88, 4220-4225
- Nathan, C. and Sporn, M. (1991) *J. Cell Biol.* 113, 981-986
- Savino, W., Villa-Verde, D.M.S. and Lannes-Vieira, J. (1993) *Immunol. Today* 14, 158-160
- Cáceres-Dittmar, G., Sánchez, M.A., Oriol, O., Kraal, G. and Tapia, F.J. (1992) *J. Invest. Dermatol.* 99, 95s-98s
- Moll, H. (1993) *Immunol. Today* 14, 383-386
- Tapia, F.J., Rojas, E., Kraal, G., Mosca, W. and Convit, J. (1988) in *The Langerhans Cell* (Thivolet, J. and Schmitt, D., eds), pp. 479-490, John Libbey
- Cáceres-Dittmar, G., Sánchez, M.A., Rondón, A.J. and Tapia, F.J. (1992) *Acta Microsc.* 1, 118-121
- Martínez-Arends, A., Tapia, F.J., Cáceres-Dittmar, G. et al. (1991) *Acta Trop.* 49, 271-280
- Tapia, F.J., Cáceres-Dittmar, G., Sánchez, M.A., Fernández, C.T., Rondón, A.J. and Convit, J. (1994) *Exp. Dermatol.* 3, 17-22
- Zhou, L.-J., Schwarting, R., Smith, H.M. and Tedder, T.F. (1992) *J. Immunol.* 149, 735-742
- Lewis, R.E., Buchsbaum, M., Whitaker, D. and Murphy, G.F. (1989) *J. Invest. Dermatol.* 93, 672-677
- Cáceres Dittmar, G., Tapia, F.J., Sánchez, M.A. et al. (1993) *Clin. Exp. Immunol.* 91, 500-505
- Pompeu, M.L., Freitas, L.A., Santos, M.L.V., Barral, A.

- and Barral-Netto, M. (1992) *Exp. Parasitol.* 74, 169-176
- 34 Will, A., Blank, C., Rölinghoff, M. and Moll, H. (1992) *Eur. J. Immunol.* 22, 1341-1347
- 35 Giannini, M.S.H. (1986) *Infect. Immun.* 51, 838-843
- 36 van Snick, J. (1990) *Annu. Rev. Immunol.* 8, 253-278
- 37 Cillari, E., Dieli, M., Maltese, E. *et al.* (1989) *J. Immunol.* 143, 2001-2005
- 38 Bradley, D.J. (1987) in *The Leishmaniases* (Vol. 2) (Peters, W. and Killick-Kendrick, R., eds), pp. 551-581, Academic Press
- 39 World Health Organization (1984) *WHO Tech. Rep. Ser.* 71
- 40 Giannini, S.H. (1992) *Parasitol. Today* 8, 44-48
- 41 Blank, C.M., Fuchs, H., Rappersberger, K., Rölinghoff, M. and Moll, H. (1993) *J. Infect. Dis.* 167, 418-425
- 42 Drijkoningen, M., De Wolf-Peeters, C., Degreef, H. and Desmet, V. (1988) *Arch. Dermatol. Res.* 280, 220-227
- 43 Romagnani, S. (1992) *Immunol. Today* 13, 379-381
- 44 Titus, R.G. and Ribeiro, J.M.C. (1990) *Parasitol. Today* 6, 157-160
- 45 Lerner, E.A. and Shoemaker, C.B. (1992) *J. Biol. Chem.* 267, 1062-1066
- 46 Samuelson, J., Lerner, E.A., Tesh, R. and Titus, R.G. (1991) *J. Exp. Med.* 173, 49-54