

Capillary Changes in Skeletal Muscle of Patients With Essential Hypertension

NOELINA HERNÁNDEZ,^{1*} SONIA H. TORRES,¹ HÉCTOR J. FINOL,²
AND OMAIRA VERA³

¹Institute of Experimental Medicine, Faculty of Medicine, Central University of Venezuela, Caracas 1050, Venezuela

²Center of Electron Microscopy, Faculty of Science, Central University of Venezuela, Caracas 1050, Venezuela

³University Hospital of Caracas, Central University of Venezuela, Caracas 1050, Venezuela

ABSTRACT

Arterial hypertension produces changes along the vascular tree. However, there are few reports on its effect on human muscle capillaries. This study demonstrates the effects of essential hypertension on the capillaries of human *quadriceps* muscle.

Muscle biopsy was taken from *quadriceps femoris* in eight men with recent diagnosis of essential hypertension, without treatment. Biopsies were also taken from eight normotensive men and were used as controls. Fiber types were classified by ATPase reaction, capillaries counted in α -amylase-PAS stained sections and ultrastructure studied by conventional methods of transmission electron microscopy.

No changes were found in capillaries or muscle fiber types by histochemical methods. However, electron microscopy revealed abnormal capillaries with endothelial cells infoldings into the lumen, as well as occluded or degenerated capillaries. In some cases the endothelial cell area covered by pericytes was increased. Basement membrane of capillaries was frequently increased in width, sometimes irregularly, and in other instances it was reduplicated. In transversely sectioned capillaries lumen diameter was reduced and wall thickness was increased, although total diameter was unchanged.

In hypertensive patients the finding of some degenerated capillaries adjacent to muscle fibers could be interpreted as the beginning of a process of rarefaction. Some capillaries showed morphological changes, and the ratio wall thickness/lumen was increased. Anat Rec 256:425–432, 1999.

© 1999 Wiley-Liss, Inc.

Key words: hypertension; muscle capillaries; muscles fiber types; pericytes; endothelial cells

Rarefaction in skeletal muscle of hypertensive rats is well documented. Prewitt et al. (1982) showed in spontaneously hypertensive rats (SHR) that functional rarefaction preceded anatomical rarefaction. In another model of hypertension, produced by reduction of renal mass, followed by salt loading, degeneration of capillaries was found in the cremaster muscle, supporting the concept of anatomic rarefaction (Hansen-Smith et al., 1990). Rats made hypertensive by deoxycorticosterone and salt loading also had signs of reduction in muscle capillary number (Hernández et al., 1996). Rarefaction was shown in cremas-

ter muscle even in sham-operated rats on a high salt diet (Hansen-Smith et al., 1996). However, not all studies in experimental models of hypertension described a decrease

Grant sponsor: "Consejo de Desarrollo Científico y Humanístico"; Grant number: 09.332772/96 and "Coordinación de Investigación, Facultad de Medicina" U.C.V.

*Correspondence to: Noelina Hernández, Ph.D., Instituto de Medicina Experimental, Apdo. 50587, Sabana Grande, Caracas 1050, Venezuela. E-mail: hernandn@camelot.rect.ucv.ve

Received 17 February 1999; Accepted 27 July 1999

in capillarity, as demonstrated in SHR by Gray (1988) and Ben Bachir-Lamrini et al. (1990), and in muscles of one-kidney one-clip hypertension, by Saito et al. (1991).

In hypertensive man, it is more difficult to correlate capillary changes with disease because other processes that affect blood vessels such as diabetes and/or dislipidemias often accompany essential hypertension. Moreover, it is difficult to know with certitude the time elapsed since the beginning of the disease, and last but not least, the subjects of the studies are often treated with antihypertensive drugs that modify capillarity (Torres et al., 1994).

Capillary density was reduced in quadriceps and pectoralis major muscles studied at autopsy in a heterogeneous group of hypertensive patients, treated by a continuous antihypertensive therapy (Henrich et al., 1988). On the other hand, hypertensive patients were found to have less proportion of type I muscle fibers, which are the ones that have more capillaries surrounding them. It was also shown that blood pressure, both in normo- and hypertensive patients, was inversely correlated to the percentage of type I fibers (Juhlin-Dannfelt et al., 1979).

Capillaries have also been found reduced in retina of patients with essential hypertension (Wolf et al., 1994) and in the conjunctival microvasculature of young patients with borderline hypertension (Sullivan et al., 1983).

In the present work we studied a group of recently diagnosed essential hypertensive patients, which had not received any antihypertensive treatment. Needle biopsy of quadriceps muscle was performed, capillaries and fiber types were quantified by histochemistry at light microscopy, and ultrastructural features were examined for assessment of capillary alterations.

MATERIALS AND METHODS

Patients were selected from a group of manual workers of the Central University of Venezuela. They were studied at the "Medicine Service no. 1" of the University Hospital in Caracas. The Ethics Committee of the Hospital approved the project and the subjects gave written consent. Controls were postgraduate students or teaching and medical staff from the same university. Blood pressure was measured with the subjects in seated position, three times with an interval of 3 min. The subjects were selected for the hypertensive group when mean blood pressure of the three measures was above 140 mm Hg systolic and above 90 mm Hg diastolic, and provided that clinical examination and routine laboratory exams did not show any other diseases. They were evaluated in a second occasion in fasting conditions, after 2 weeks; blood pressure measurements were repeated and blood samples were taken for analysis. After another 2 weeks patients blood pressure was checked again and muscle biopsy was taken at rest with a Bergstrom needle (Bergstrom, 1962) from the vastus lateralis part of *quadriceps femoris* muscle, with the usual antiseptic precautions and after skin anesthesia with 2% xylocaine. Hypertensive group was formed by eight men (40.6 ± 0.9 years old) with recent diagnosis of essential hypertension; the patients did not receive treatment until the muscle sample was removed. Biopsies were also taken from a control group of eight normotensive men (35.5 ± 2.7 years old).

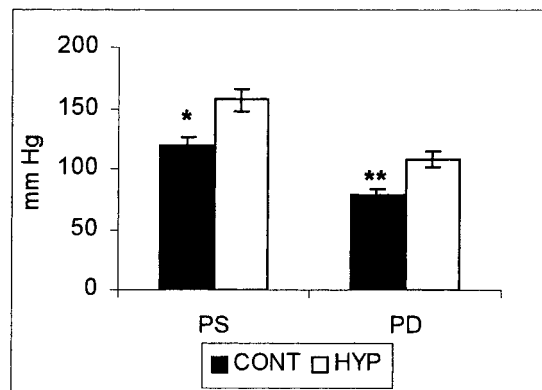


Fig. 1. Systolic blood pressure (SP) and diastolic blood pressure (DP) in control (cont) and hypertensive patients (hyp). Mean values \pm SEM. * $P \leq 0.025$; ** $P \leq 0.005$.

The muscle sample was divided in two, one part was extended longitudinally on a cork and pinned at both ends approximately at rest length, fixed in 3% cold glutaraldehyde in phosphate buffer at pH 7.4 and 320 mOsmol. After fixation the sample was divided in small blocks and postfixed in 1% OsO₄, dehydrated in ethanol and embedded in Epon. Ultrathin sections were stained with uranyl acetate and lead citrate and observed in a Hitachi H-500 transmission electron microscope. Six blocks (2 mm length \times 1 mm diameter) were taken from each muscle sample. Three grids were prepared from each block at different depths for a total of 18 sections. All capillaries that were oriented in transverse sections were chosen for measurements of lumen and wall thickness (Friedman et al., 1971). Photomicrographs at magnification 22,400 \times were used to measure whole capillary and lumen surface by planimetry. Wall surface was the difference between the two measurements. Twenty-five capillaries from the hypertensive group were measured and 20 capillaries from the control group.

The other part of the sample was used for light microscopy. It was embedded in OCT (Tissue Tek II) and frozen in isopentane cooled in liquid nitrogen. Serial 10 μ m sections were cut in a cryostat at -20°C , the adenosine triphosphatase (ATP-ase) reaction was carried out after preincubation at acid pH 4.37, 4.6 and 4.8, and basic pH 10.3 (Brooke and Kaiser, 1970), and fiber types were classified. Capillaries were visualized with the α -amylase-PAS reaction (Andersen, 1975). Not less than 200 fibers were classified in each muscle. As each fiber could be identified in both the ATPase and PAS stained sections, classification could be transferred to photomicrographs of the PAS slides, made at a final magnification $\times 200$, which were used to measure fiber areas. An area of the photomicrograph was delineated and measured by planimetry, and fibers and capillaries were counted to calculate the mean area of the fibers, capillaries/mm², and capillary/fiber ratio. All fibers of one type in each muscle section photomicrograph were copied in a transparent paper one beside the other like a puzzle, and the area was measured by planimetry to calculate the mean area of each fiber type.

Results were analyzed statistically by the non-paired Student's *t*-test. The null hypothesis was rejected at a

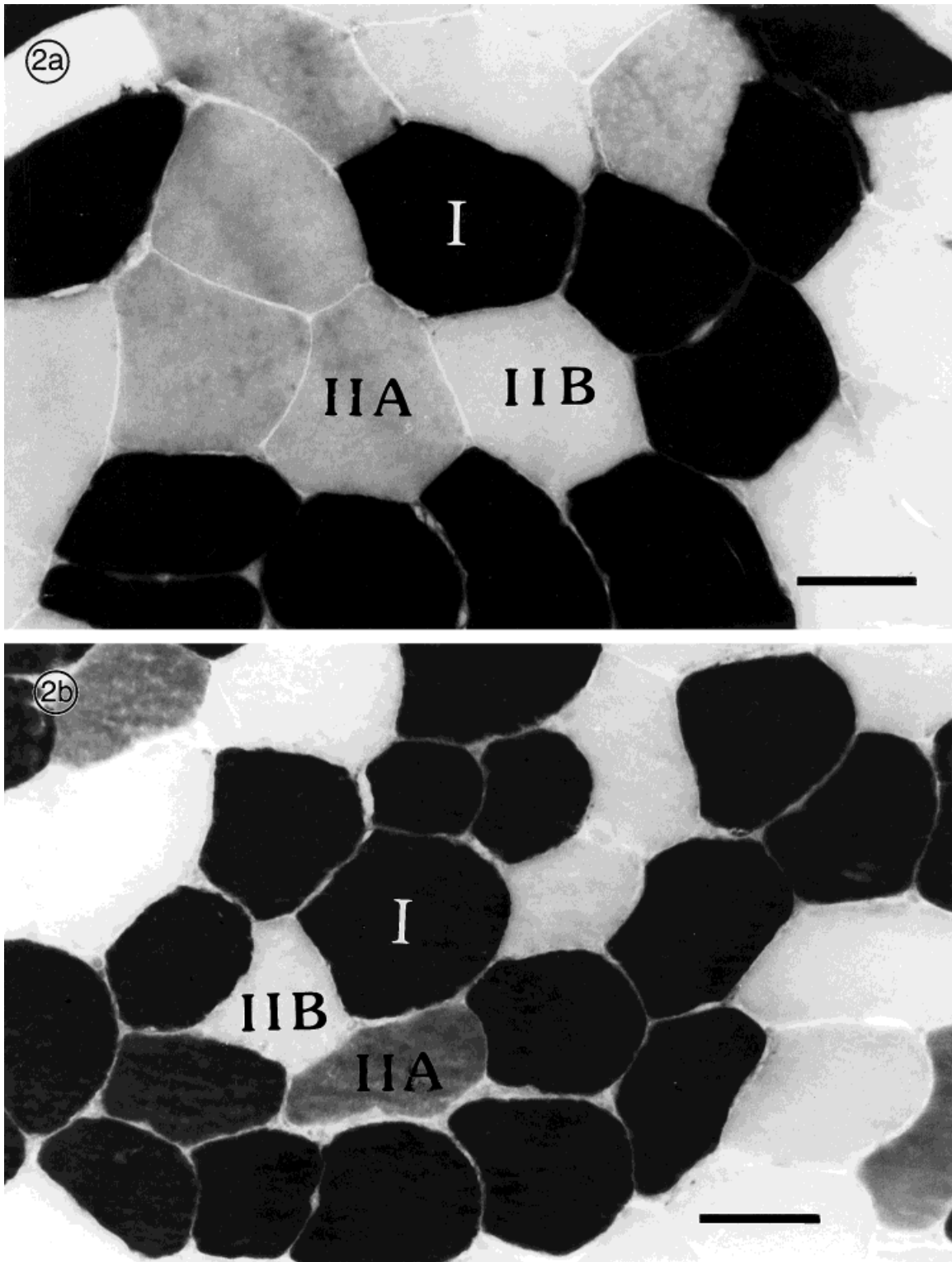


Fig. 2. Photomicrograph of ATPase stain, preincubation at pH 4.37. **a:** Control. **b:** Hypertensive patient. In these sections the three muscle fiber types IIA, IIB and I can be seen. Scale bar = 20 μ m.

TABLE 1. Percentage of fiber types in quadriceps muscle of control and hypertensive subjects*

Fiber type (%)	Control	Hypertensive
Type I	39 ± 1.86 (8)	40.8 ± 3.36 (8)
Type IIA	29.65 ± 4.89 (8)	25.5 ± 2.07 (7)
Type IIB	31.36 ± 3.81 (8)	30.56 ± 2.44 (7)

*Mean values ± SEM. In parentheses, number of analyzed muscles.

TABLE 2. Fiber areas in quadriceps muscle of control and hypertensive subjects*

Fiber area (μm ²)	Control	Hypertensive
Mean	6369 ± 668 (8)	6003 ± 703 (8)
Type I	6983 ± 732 (8)	6707 ± 811 (8)
Type IIA	6085 ± 726 (8)	6101 ± 952 (7)
Type IIB	6813 ± 676 (8)	5806 ± 772 (7)

*Mean values ± SEM. In parentheses, number of analyzed muscles.

TABLE 3. Capillary/fiber index, capillary density (capillaries/mm²), and mean number of capillaries adjacent to each fiber in quadriceps muscle of control and hypertensive subjects*

	Control	Hypertensive
Capillary/fiber	2.48 ± 0.12 (8)	2.23 ± 0.08 (8)
Capillaries/mm ²	390 ± 38.58 (8)	389 ± 35.93 (8)
Capillaries adjacent to fiber I	6.93 ± 0.22 (8)	6.51 ± 0.21 (8)
Capillaries adjacent to fiber IIA	6.54 ± 0.40 (8)	5.75 ± 0.30 (7)
Capillaries adjacent to fiber IIB	6.44 ± 0.33 (8)	5.85 ± 0.16 (7)

*Mean values ± SEM. In parentheses, number of analyzed muscles.

probability level of 0.05. The results are expressed as mean ± standard error of mean.

RESULTS

Figure 1 shows systolic and diastolic blood pressure in the hypertensive patients and in the control subjects.

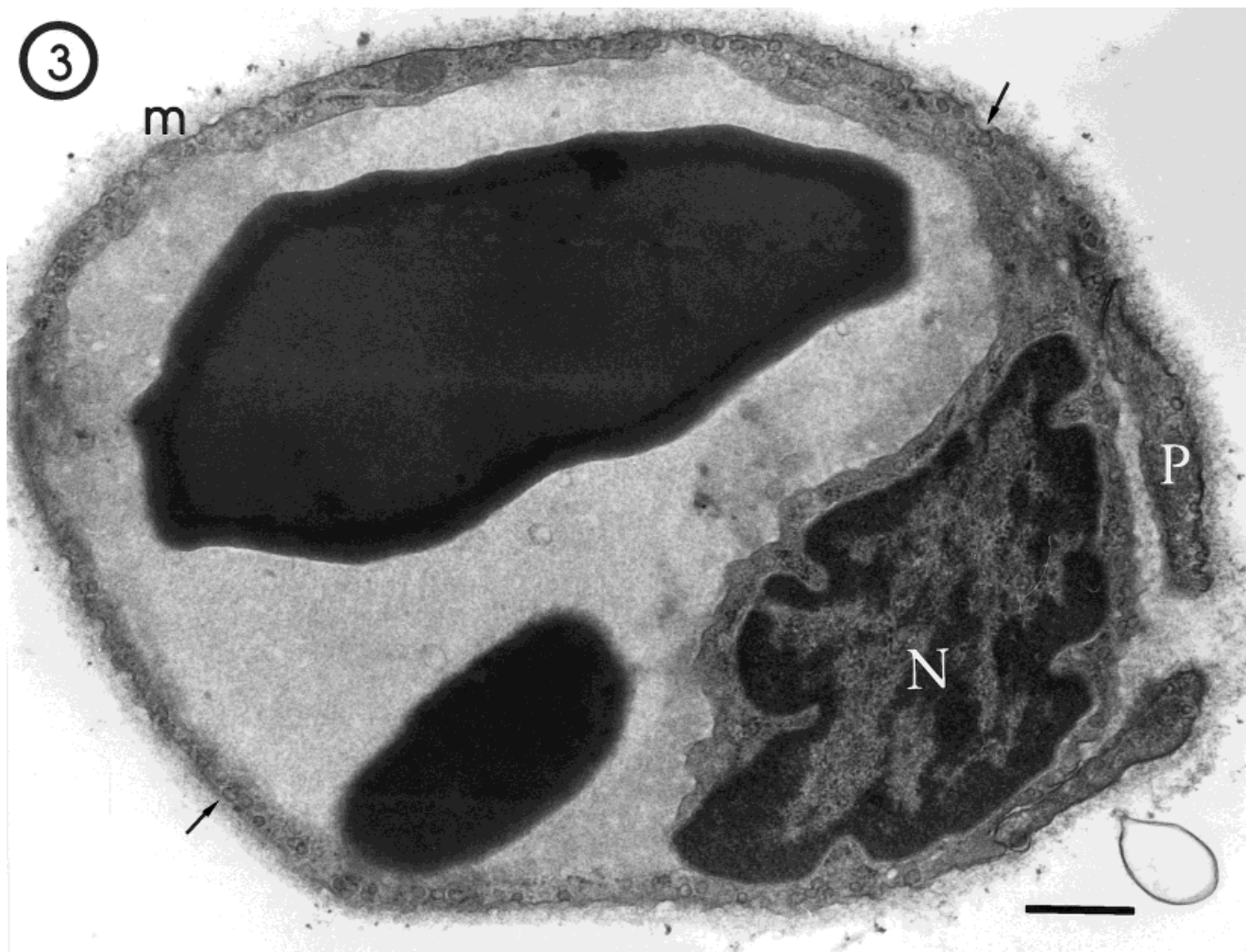


Fig. 3. Electron micrograph of a section of quadriceps muscle in a control subject (43 years old). N, nucleus; m, thin basement membrane; P, pericyte; Arrows, pinocytotic vesicles. Scale bar = 0.5 μm.

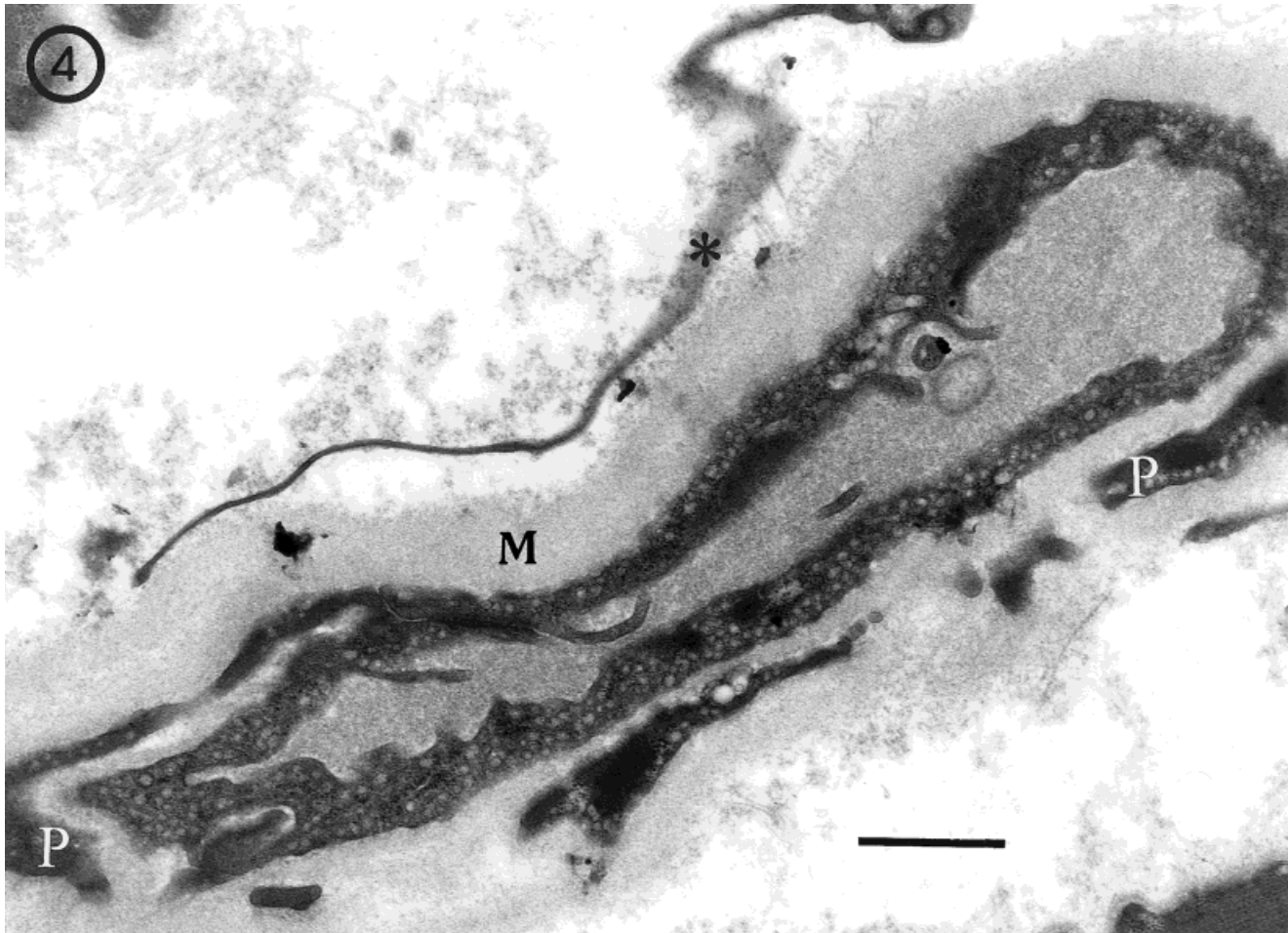


Fig. 4. Section of quadriceps muscle in a hypertensive patient subject (40 years old). The pericyte (P) covers more than 33% of the surface of the endothelium. M, thickened basal membrane. Note the prolongation of a macrophage (asterisk). Scale bar = 1 μ m.

Transversal sections of quadriceps muscle of a control (Fig. 2A) and a hypertensive patient (Fig. 2B) are shown in Figure 2.

Fiber type proportions (Table 1) and fiber areas (Table 2) were not different in hypertensive patients compared to controls. Also capillary number and indexes were similar in patients and control subjects (Table 3).

Figure 3 is an electron micrograph from the quadriceps muscle in a control subject. Note the capillary circular shape in the transversal section, a thin basement membrane and the abundance of pinocytotic vesicles. In the muscles of patients, capillary basement membrane was frequently increased in width (Figs. 4, 5 and 6), sometimes irregularly, and in other instances it was delaminated (Figs. 4 and 6). Capillary endothelial cells had surface infoldings into the lumen and cytoplasmic vacuoles (Fig. 6). Some capillaries were partially (Fig. 6) or totally (Fig. 5) occluded or degenerated (Figs. 5 and 6). The area covered by pericytes in the transverse section was normal in some capillaries (less than 24%; Tilton et al., 1979), but in others it was larger (Fig. 4). Some macrophages (Fig. 4), mast cells, lymphocytes and few plasma cells and polymorphonuclear leukocytes were found in the extracellular

space, which is very rare in normal muscle. Some pericytes were large and showed altered structure (Fig. 5).

The cross section of the capillaries was measured and the wall/lumen ratio was calculated. It was found that the cross section of the capillaries was similar in the hypertensive and control groups (Table 4), although the lumen diameter was smaller and the thickness of the wall (only endothelial cell without pericyte) was increased in the hypertensive patients (Table 4). The wall/lumen ratio was higher in the hypertensive patients compared to the control group (Table 4).

DISCUSSION

We did not find a significant decrease in the number of capillaries expressed either as capillary per fiber or as capillary density in vastus lateralis muscle from hypertensive patient. The number of capillaries adjacent to the different fiber types was diminished, but the difference was not statistically significant (Table 3). There are few studies to compare these results. Henrich (1988) included in his study patients with diabetes and other pathological

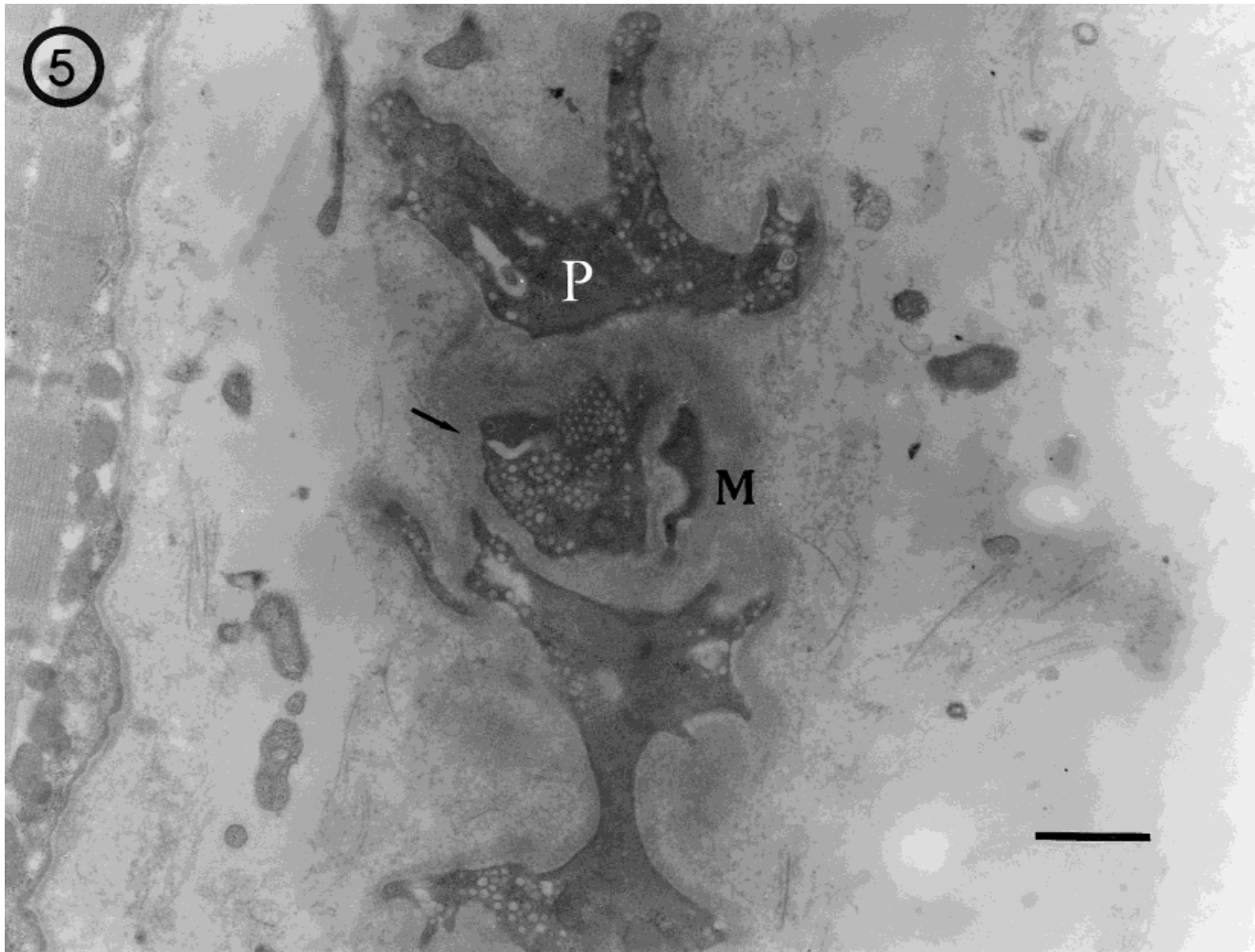


Fig. 5. Electronic micrograph of a section of quadriceps muscle in a hypertensive patient (40 years old). Degenerated endothelium (arrow) is totally covered by thickened basement membrane (M). P, large pericyte with diffuse structure. Note the abundance of pinocytotic vesicles. Scale bar = 2 μ m.

entities as well as patients with different treatments; both variables could have modified capillary number.

The present group of hypertensive patients did not have other diseases that could modify capillaries and was not subjected to medication. The other variable, that is duration of the hypertensive state was not under our control.

It is possible that destruction of capillaries was not enough widespread to be detected in the histochemical method. Another possibility is that the disease has not been present for a sufficient length of time to produce rarefaction. However, alterations suggestive of capillary destruction as degeneration and closure of capillaries were found in the ultrastructural examination of muscle. In addition, there was an increase in the endothelial area covered by pericytes. Hirschi and D'Amore (1996) demonstrated in cell cultures that pericytes that come into contact with endothelial cells that are forming new vessels exert an inhibitory effect on their proliferation. Thus hypertrophied pericytes may have induced endothelium degeneration and disappearance of capillaries (Fig. 5). Signs of capillary destruction at ultrastructural level were

found in an experimental group of DOCA-salt hypertensive rats, at 7 weeks after the beginning of the administration of DOCA-salt with no reduction of capillary indexes. However, after 14 weeks, rarefaction was also demonstrated by histochemical light microscopy (Hernández et al., 1996).

The most pronounced change in capillary structure was the increase in wall thickness, $1.51 \pm 0.13 \mu\text{m}$ in control to $2.94 \pm 0.20 \mu\text{m}$ in hypertensive, without change in the diameter of the vessels. Remodeling has been shown in arterioles in hypertension and is produced by regrouping of smooth muscle cells (Mulvany and Aalkjaer, 1990). The lumen of arteries in gluteal subcutaneous biopsies from hypertensive patients was 25% smaller than in control subjects (Schiffrin, 1992). However, the present change in capillaries only involves endothelial cells and may be a consequence of reduced inflow (functional rarefaction) distal to small arteries with reduced lumen.

The endothelial infoldings into the lumen may also contribute to its reduction. This alteration, together with thickening and reduplication of basement membrane has

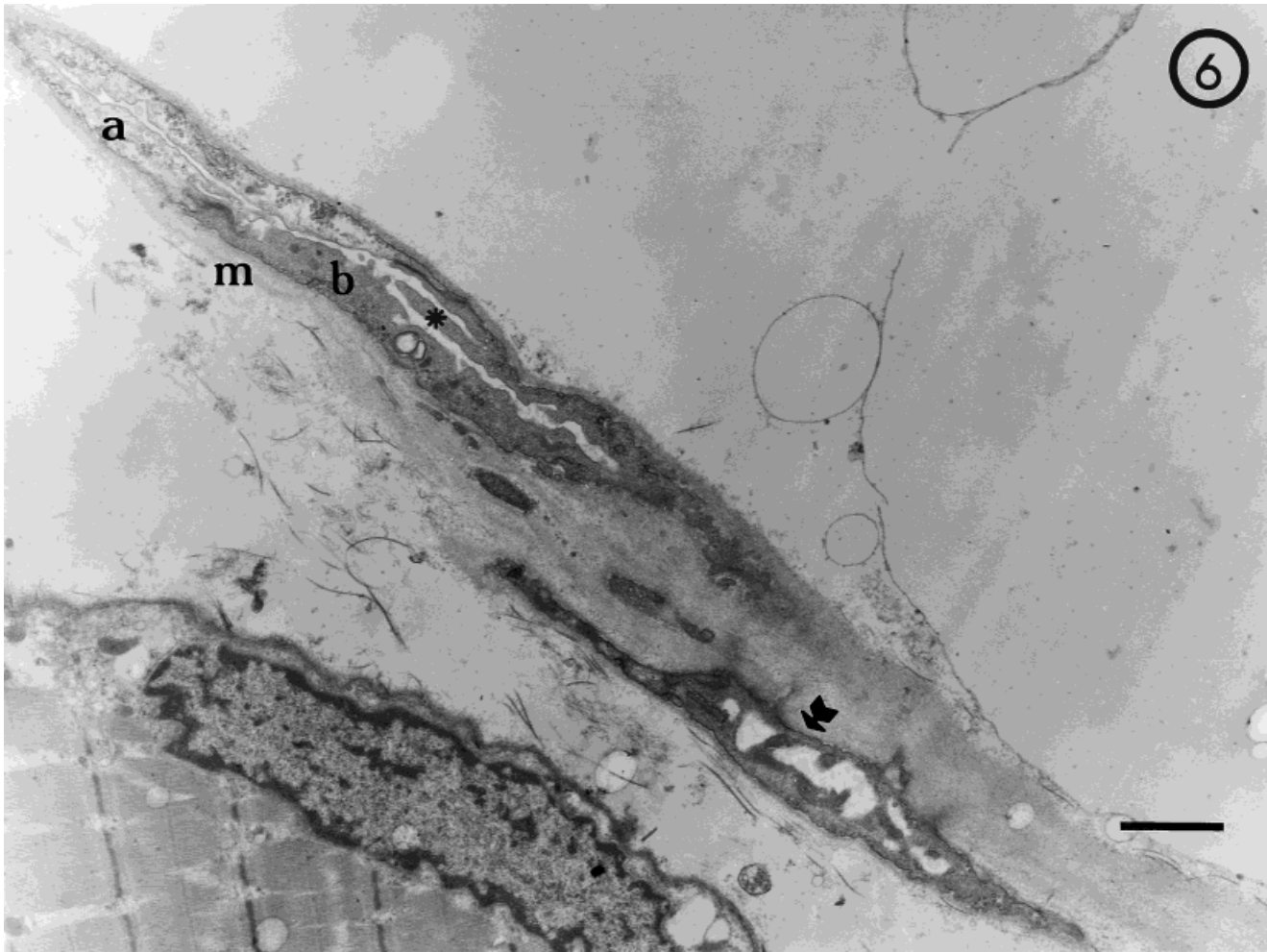


Fig 6. Electron micrograph of a section of quadriceps muscle in a hypertensive patient (42 years old). Partially occluded capillaries. One has lost its structure (arrow). Two endothelial cells of one capillary showing different cytoplasm electron density (a, b). Note infolding of endothelial cell (asterisk). Thickened and delaminated basement membrane (m). Scale bar = 2 μ m.

TABLE 4. Capillary diameter in cross-sections of quadriceps muscle of control and hypertensive subjects*

Capillaries	Control	Hypertensive	Significance
Lumen diameter (μ m)	4.86 \pm 0.22 (20)	2.82 \pm 0.20 (25)	$P \leq 0.0001$
Diameter (μ m)	6.39 \pm 0.27 (20)	5.84 \pm 0.39 (25)	NS
Wall thickness (μ m)	1.51 \pm 0.13 (20)	2.94 \pm 0.20 (25)	$P \leq 0.0001$
Wall/lumen ratio	0.31 \pm 0.031 (20)	1.18 \pm 0.11 (25)	$P \leq 0.0001$

*Mean values \pm SEM. NS, not significant. In parentheses, number of analyzed capillaries.

been found in many conditions in which degeneration or regeneration of capillaries are involved (Finol et al., 1986). On the other hand, some of the hypertensive patients in the present study were hiperinsulinemic (unpublished results), and would potentially develop non-insulin dependent diabetes. Basement membrane thickening is characteristic of diabetic patients even before the appearance of the disease (Siperstein et al., 1968).

In conclusion, although no decrease in capillary numbers was found in skeletal muscle of hypertensive patients,

the ultrastructural examination showed evidence of capillary degeneration and destruction.

ACKNOWLEDGMENTS

This study was supported by grants 09.332772/96 from the "Consejo de Desarrollo Científico y Humanístico" and help from the "Coordinación de Investigación, Facultad de Medicina," Central University of Venezuela. Caracas, Venezuela.

LITERATURE CITED

- Andersen P. 1975. Capillary density in skeletal muscle of man. *Acta Physiol Scand* 95:203–205.
- Ben Bachir-Lamrini L, Sempore B, Mayett M-H, Favier RJ. 1990. Evidence of a slow-to-fast fiber type transition in skeletal muscle from spontaneously hypertensive rats. *Am J Physiol* 27:R352–R357.
- Bergstrom J. 1962. Muscle electrolytes in man. *Scand J Clin Lab Invest* 68 (Suppl): 1–110.
- Brooke MH, Kaiser KK. 1970. Muscle fiber types. How many and what kind? *Arch Neurol* 23:369–379.
- Finol HJ, Muller B, Torres SH, Domínguez JJ, Perdomo P, Montes de Oca I. 1986. Ultrastructural abnormalities in muscular vessels of hyperthyroid patients. *Acta Neuropathol (Berl)* 71:64–69.
- Friedman SM, Nakashima M, Mar MA. 1971. Morphological assessment of vasoconstriction and vascular hypertrophy in sustained hypertension in the rat. *Microvasc Res* 3:416–425.
- Gray SD. 1988. Histochemical analysis of capillary and fiber-type distributions in skeletal muscles of spontaneously hypertensive rats. *Microvasc Res* 36:228–238.
- Hansen-Smith FM, Greene AS, Cowley AW Jr, Lombard JH. 1990. Structural changes during microvascular rarefaction in chronic hypertension. *Hypertension* 15:922–928.
- Hansen-Smith FM, Morris LW, Greene AS, Lombard JH. 1996. Rapid microvessel rarefaction with elevated salt intake and reduced renal mass hypertension in rats. *Circ Res* 79:324–330.
- Henrich HA, Romen W, Heigärtner W, Hartur E, Bäumer F. 1988. Capillary rarefaction characteristic of skeletal muscle of hypertensive patients. *Klin Wochenschr* 66:54–60.
- Hernández N, Torres SH, Finol HJ, Sosa A, Cierco M. 1996. Capillary and muscle fiber type changes in DOCA-salt hypertensive rats. *Anat Rec* 246:208–216.
- Hirschi KK, D'Amore PA. 1996. Pericytes in the microvasculature. *Cardiovasc Res* 32:687–698.
- Juhlin-Dannfelt A, Frisk-Holmberg M, Karlsson J, Tesch P. 1979. Central and peripheral circulation in relation to muscle-fibre composition in normo- and hypertensive man. *Clin Sci* 56:335–340.
- Mulvany MJ, Aalkjaer C. 1990. Structure and function of small arteries. *Physiol Rev* 70:921–961.
- Prewitt RL, Chen IHH, Dowell R. 1982. Development of microvascular rarefaction in the spontaneously hypertensive rat. *Am J Physiol* 243:H243–H251.
- Saito Y, Sakanaki T, Ono Z, Sato K, Yagi A, Sakamoto H, Murata K. 1991. Alterations of skeletal muscle fiber types and microvasculature in renovascular hypertensive rats. *Proceedings Fifth World Congress for Microcirculation*, 561,94 (Abstr).
- Schiffirin EL. 1992. Reactivity of small blood vessels in hypertension: relation with structural changes. State of the art lecture. *Hypertension* 19 [Suppl II]:II1–II9.
- Siperstein MD, Unger RH, Madison LL. 1968. Studies of muscle capillary basement membranes in normal subjects, diabetic, and prediabetic patients. *J Clin Invest* 47:1973–1999.
- Sullivan JM, Prewitt RL, Josephs JA. 1983. Attenuation of the microcirculation in young patients with high-output borderline hypertension. *Hypertension* 5:844–851.
- Tilton RG, Kilo C, Williamson JR. 1979. Pericyte-endothelial relationships in cardiac and skeletal muscle capillaries. *Microvasc Res* 18:325–335.
- Torres SH, Kaswan D, Andújar J, Garmendia J, Hernández N. 1994. Effect of vasoactive drugs on muscle fibre types and capillaries. *Acta Cient Venez* 45:199–206.
- Wolf S, Arend O, Schulte K, Ittel TH, Reim M. 1994. Quantification of retinal capillary density and flow velocity in patients with essential hypertension. *Hypertension* 23:464–467.