

ORGAN-SPECIFIC IMMUNITY IN CANINE VISCERAL LEISHMANIASIS: ANALYSIS OF SYMPTOMATIC AND ASYMPTOMATIC DOGS NATURALLY INFECTED WITH *LEISHMANIA CHAGASI*

MARTIN A. SANCHEZ,* NILKA L. DIAZ,* OLGA ZERPA, EMILIA NEGRON, JACINTO CONVIT, AND FELIX J. TAPIA
Laboratorio de Biología Molecular, Instituto de Biomedicina, Universidad Central de Venezuela, Caracas, Venezuela

Abstract. We characterized key leukocyte immunophenotypes in the liver and spleen of naturally infected dogs from an area in Venezuela endemic for leishmaniasis. Dogs were classified as symptomatic or asymptomatic after serologic and physical analysis. Symptomatic dogs showed a higher parasite burden in the liver and spleen than asymptomatic dogs. The livers of asymptomatic dogs showed an effective immunity with well-organized granulomas walling off parasites in an environment of central memory CD44^{lo}, CD45RO^{hi}, activated effector CD44^{hi}, and CD45RO^{hi} T cells. These granulomas also had many major histocompatibility class II+ cells and CD11c+ dendritic cells, and cells expressing CD18 and CD44. In contrast, symptomatic livers showed a non-organized and non-effective infiltrate composed of T cells and heavily parasitized Kupffer cells and a diminished expression of activation molecules. In the spleen, the immune responses of symptomatic and asymptomatic dogs were very similar. The results showed a distinct immune response against *Leishmania chagasi* in target organs.

INTRODUCTION

In Europe and Latin America, *Leishmania infantum* and *L. chagasi* are the causative agents of visceral leishmaniasis (VL), a potentially fatal disease in humans and domestic dogs if not diagnosed and treated in a timely manner.¹ Since dogs are the main reservoir, infected domestic dogs probably represent the main source of infection in Venezuela.^{2,3} Once infected sand flies transmit the parasites to the vertebrate host, the parasite migrate to the viscera and establish establishing infections in the liver, spleen, and bone marrow.^{4,5}

Although there is some evidence regarding the immune response of target organs against *Leishmania* parasites from murine models,⁵ little is known of the specific immune responses occurring in these organs in both human and canine leishmaniasis. Based on the similarity of clinical signs observed in humans and dogs, canine VL has been suggested as a good model to comprehend the pathogenesis of the human disease. However, experimental infections in dogs are expensive and time-consuming, and findings are inconsistent when compared with those in well-established murine models.⁶ Conveniently, naturally infected dogs represent an excellent model since these animals show a wide range of clinical signs and symptoms observed in human infection.

A few studies support the association between disease progression and the establishment of cell-mediated immunity dogs. Several investigators have shown the lack of specific cell-mediated immunity in infected symptomatic dogs characterized by a reduced lymphoproliferative response to *Leishmania* antigens and a decrease in CD4+ T cells.^{7–9}

One study using peripheral blood mononuclear cells (PBMC) from experimentally infected dogs suggest an association between a Th1 response and resistance to canine VL.¹⁰ In contrast, a similar study in Brazil using bone marrow aspirates from naturally infected dogs failed to provide a clear association between Th2 cytokine patterns, humoral responses, and cellular responses in the progression of visceral disease.¹¹ These studies provide only a broad depiction of the cell-mediated immunity response that does not necessarily reflect the response in the viscera. The *in situ* immune re-

sponse in target organs of the dog against viscerotropic *Leishmania* has not been extensively studied. A study by Tafuri and others¹² has described histopathologic changes in the livers and spleens of dogs naturally and experimentally infected with *L. chagasi* and demonstrated increased numbers of CD18+ cells in the spleens of these animals. In the present study, we characterize the *in situ* immune response in the livers and spleens of naturally infected dogs from endemic areas for leishmaniasis on Margarita Island in Venezuela and show differences between symptomatic and asymptomatic dogs.

MATERIALS AND METHODS

Animals. Domestic, half-breed, naturally infected dogs (34 males and 26 females) between one and seven years of age from areas endemic for *L. chagasi* on Margarita Island (Nueva Esparta State) in Venezuela were diagnosed by serologic and parasitologic methods as previously described.^{3,13} After a physical examination, positive dogs were classified as asymptomatic (n = 41) or symptomatic (n = 19) as described by Zerpa and others^{3,13} in relation to the absence or presence of some or all of the following clinical signs: weigh loss, ocular and nail changes (corneal opacity and onychogryphosis), alopecia, skin ulcers, hepatosplenomegaly, and palpable lymph nodes. Healthy control dogs (n = 5) were obtained from an area that was not endemic for VL (Unidad de Cirugía Experimental, Escuela de Medicina Vargas, Caracas, Venezuela). The Institutional Animal House and Ethical Committee of the Universidad Central de Venezuela reviewed and approved all protocols. Killing of animals followed the report of the American Veterinary Medical Association Panel on Euthanasia using pentobarbital. The Venezuelan Program on Prevention and Control of Visceral Leishmaniasis required the killing of all infected animals.

Parasite load in dogs naturally infected with *L. chagasi*. The liver and spleen were aseptically removed and transverse sections were cut using a scalpel to prepare impression smears on glass slides from a representative sample (six asymptomatic dogs and five symptomatic dogs). These smears were fixed in methanol and stained with Giemsa (British Drug Houses, Leicestershire, United Kingdom) to identify

* These authors contributed equally to this paper.

host and parasite nuclei. Parasite load was expressed either as Leishman Donovan units (LDU) (number of amastigotes per 1,000 host cell nuclei per gram of organ) or as the number of parasites per 1,000 host nuclei. Also, 3- μm cryostat sections of liver and spleen from all the dogs ($n = 60$) and the mesenteric lymph nodes from 10 dogs (five asymptomatic and five symptomatic) were fixed in methanol, stained with Giemsa, and embedded in distyrene-tricrecyl phosphate-xylene (DPX) mounting medium (British Drug Houses), and the number of infected cells/ mm^2 was counted under the microscope.

Reagents and antibodies. The following primary antibodies were used for immunocytochemical analysis: rat anti-canine CD4 (T helper-inducer, YKIX302.9), CD8 (T suppressor-cytotoxic, YCATE55.9), Pan T cells Thy-1 (T cells and monocytes, YKIX337.217), CD45 (T cell subgroup, YKIX716.13), CD44 (YKIX337.8.7), major histocompatibility class II (MHC II) (YKIX334.2), rat anti-human CD18 (YFC118.3), mouse anti-canine CD11c (dendritic cells, monocytes, and granulocytes, CA11.CA1), mouse anti-human monocytes-macrophages (MoMa) (MAC387) (Serotec Oxford, United Kingdom). *Leishmania* parasites were detected by immunocytochemical analysis using an affinity-purified antibody developed in our laboratory and obtained from rabbits after immunizations with a pool of parasites causing American leishmaniasis. The secondary antibodies used were mouse-absorbed biotinylated rabbit anti-rat IgG, biotinylated horse anti-mouse IgG, and biotinylated goat anti-rabbit IgG (Vector Laboratories, Burlingame, CA). The following reagents were used for flow cytometry analysis: phycoerythrin (PE)-conjugated mouse anti-human CD45RO (UCHL-1), fluorescein isothiocyanate (FITC)-conjugated rat anti-porcine CD44 (MAC329), mouse IgG2b-PE (MOPC-195), and rat IgG1-FITC (LO-DNP-1) for isotype control. Double labeling with rat anti-dog FITC-conjugated CD4 and PE/Cy5-conjugated CD8 (Serotec) were used as controls.

Immunohistologic analysis. Liver and spleen specimens from all 60 dogs and the mesenteric lymph nodes from 10 dogs (five asymptomatic and five symptomatic) were embedded in Cryomatrix™ resin (Shandon Pittsburgh, PA), snap-frozen in liquid nitrogen, and stored at -70°C until examination. Frozen sections (6 μm) were cut with a cryostat, placed on poly-L-lysine-coated glass slides, and air-dried overnight before the immunostaining. Samples were fixed in ice-cold acetone for 10 minutes, then hydrated in phosphate-buffered saline (PBS). Before immunostaining, endogenous peroxidase activity was quenched by incubating samples with 0.3% hydrogen peroxide (Sigma, St. Louis, MO) in methanol for 20 minutes. Sections were then washed in three changes of PBS for 30 minutes. Endogenous biotin was blocked in liver sections with avidin-biotin (Vector Laboratories) for 30 minutes. Background staining was blocked with 3% (v/v) serum (obtained from the same animal source of the secondary antibody) diluted in PBS for 30 minutes. Excess serum was blotted from the sections. Sections were incubated with the primary antibody for 60 minutes, washed for five minutes in PBS, and then incubated for 30 minutes with a biotinylated secondary antibody (5 $\mu\text{g}/\text{mL}$) diluted in PBS (v/v). The sections were then washed in PBS and incubated with Vectastain® (Elite ABC kit; Vector Laboratories) at a dilution of 1:100 for 30 minutes. After a final 10-minute wash step in PBS, sections were developed for three minutes in NovaRed™

substrate (Vector Laboratories). Development was ended by immersion of slides in running tap water. Sections were counterstained by immersion for three minutes in Meyer's hematoxylin (Sigma), followed by washing in tap water. Sections were dehydrated and covered with DPX mounting medium (BDH). Omission of the primary antibody or incubation with an antibody of irrelevant specificity at the same protein concentration were used as controls.

Flow cytometry analysis. Detection of surface markers on mononuclear cell fraction from liver and spleen was done as previously described.¹⁴ Briefly, hepatic mononuclear cells were obtained from perfused and collagenase-treated livers by isolation on a Histopaque-1077® density gradient (Sigma). A spleen mononuclear cell suspension was prepared by tissue dissociation of the spleen through a 20- μm sieve (Falcon; Fisher Scientific Supplies, Miami, FL) and isolation on a Histopaque-1077® density gradient. For immunolabeling, $1-5 \times 10^5$ cells/sample were washed once in 3 mL of cold staining buffer (1% [v/v] horse serum, 0.01% [w/v] sodium azide in PBS) by centrifugation at $251 \times g$ for 10 minutes at room temperature (Sorvall®; Kendro Laboratory Products, Newtown, CT). Cells were resuspended in 50% (v/v) ice-cold horse serum for 15 minutes to prevent nonspecific binding of antibodies and incubated for 30 minutes at 4°C with primary antibody (100 μL , 1–5 $\mu\text{g}/\text{mL}$) or an isotype control antibody labeled with a fluorochrome and diluted in staining buffer. The cells were then washed in 3 mL staining buffer and resuspended in 0.5 mL of 1% (w/v) paraformaldehyde in PBS, stored in the dark at 4°C and analyzed within 24 hours. For the analysis, an FACScan with CellQuest® software (Becton Dickinson, Franklin Lakes, NJ) was used. Cells were selected in a live gate using forward and side scatter, and the differential expression of the molecules CD45RO (UCHL-1-PE) and CD44 (MAC329-FITC) was determined. Cells labeled with the respective isotype control immunoglobulin for each sample were used as negative controls.

Statistical analysis. Data are expressed as the mean \pm SEM. Comparisons between groups were analyzed by analysis of variance and the Student's *t*-test using GraphPad INSTAT-3™ software version 3.02 (GraphPad Software, San Diego, CA). *P* values < 0.05 were considered significant.

RESULTS

Parasite load in dogs naturally infected with *L. chagasi*. Analysis of the parasite load from Giemsa-stained smears in the target organs showed striking differences between asymptomatic and symptomatic naturally infected dogs. Symptomatic dogs showed high parasite burdens in the liver (747 ± 39 LDU), which was almost two-fold higher than the LDU observed in livers of asymptomatic dogs (399 ± 47 LDU) (Figure 1). We also observed this difference in the spleens of symptomatic and asymptomatic dogs. In this organ, despite the lower parasite load observed, symptomatic dogs presented a two-fold increase when compared with asymptomatic dogs (238 ± 27 LDU and 90 ± 11 LDU, respectively). We also observed more parasites per cell in the liver than in the spleen of all naturally infected dogs: 400 infected cells/ mm^2 in the liver of asymptomatic dogs and 800 infected cells/ mm^2 in symptomatic dogs, and 200 infected cells/ mm^2 in the

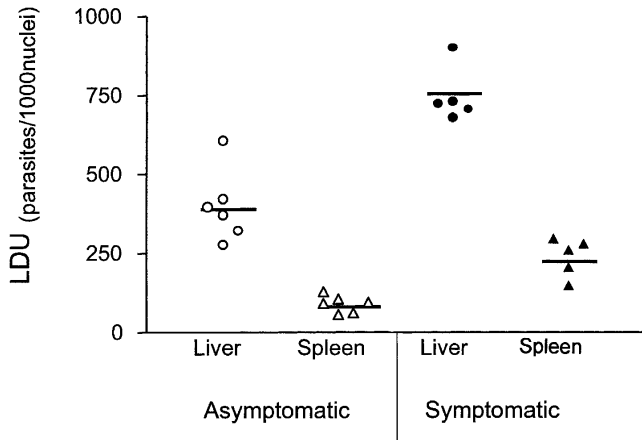


FIGURE 1. Parasite load in the liver and spleen of dogs naturally infected with *Leishmania chagasi*. The horizontal bars represent the mean. Statistically significant differences were observed between the livers ($P \leq 0.001$) and spleens ($P \leq 0.01$) of asymptomatic ($n = 6$) and symptomatic ($n = 5$) dogs, and between the two organs within each animal group ($P \leq 0.001$). LDU = Leishman Donovan units.

spleen were detected in asymptomatic dogs and 400 infected cells/mm² in symptomatic dogs. In addition, low numbers of *Leishmania*-infected cells were observed in the mesenteric lymph node in 4 of 10 dogs analyzed, with no significant differences between asymptomatic (34 infected cells/mm², $n = 2$) and symptomatic dogs (22 infected cells/mm², $n = 2$).

Differential immune response to *L. chagasi* infection in the liver and spleen of asymptomatic and symptomatic dogs. Tissue samples from dogs naturally infected with *L. chagasi* were obtained and processed for immunohistology and flow cytometry. Mature and well-organized hepatic granulomas were observed in asymptomatic dogs with a central core of Kupffer cells surrounded by infiltrating lymphocytes (Figure 2A). In symptomatic dogs, many Kupffer cells laden with parasites were scattered throughout the liver along with a profuse and disorganized mononuclear cell infiltrate (Figure 2B). In con-

trast, the spleens of symptomatic and asymptomatic dogs showed a lack of cellular and topographic organization in comparison to non-infected control dogs.

The immunohistologic analysis also demonstrated a marked difference in the proportion and distribution of immunocompetent cells in the liver, but not in the spleen, of asymptomatic dogs compared with symptomatic dogs (Figures 3, 4, and 5). Significant higher proportions of Thy-1+, CD4+, and CD8+ T cells were observed in the livers of asymptomatic dogs compared with symptomatic and healthy control dogs (Figure 4A). In contrast, similar numbers of infiltrating T cells were observed in the livers of symptomatic and healthy control dogs. Somewhat higher but significant numbers of CD4+ T cells ($P \leq 0.05$), sparsely distributed but usually localized around infected macrophages, were observed in symptomatic dogs (Figures 3 and 4A). The livers of asymptomatic dogs also showed significant higher numbers of CD18+, CD44+, and CD45+ infiltrating cells compared with symptomatic and healthy control animals, indicating the presence of highly efficient effector mechanisms (Figure 4B). Moreover, these hepatic granulomas showed higher proportions of CD11c+ and MHC-II+ cells (Figure 4C), suggesting an effective interaction between antigen-presenting cells and T cells that favor proper control of parasites. Thus, the observed lower proportion of MoMa+ Kupffer cells in the livers of asymptomatic dogs suggest that dendritic cells, not macrophages, contribute to the increased numbers of MHC-II+ and CD11c+ cells observed.

In the spleen, both symptomatic and asymptomatic dogs showed similar immune responses, despite a two-fold difference in the parasite load observed in these two clinical conditions (Figure 5). Higher numbers of CD4+ T cells and CD44+ cells were observed in the spleens of asymptomatic dogs compared with symptomatic and healthy control dogs (Figure 5).

In the mesenteric lymph node, a group of symptomatic ($n = 5$) and asymptomatic ($n = 5$) dogs showed similar parasite loads and immune responses regarding CD4+ T cells and CD11c+ cells, whereas the number of CD8+ T cells was sig-

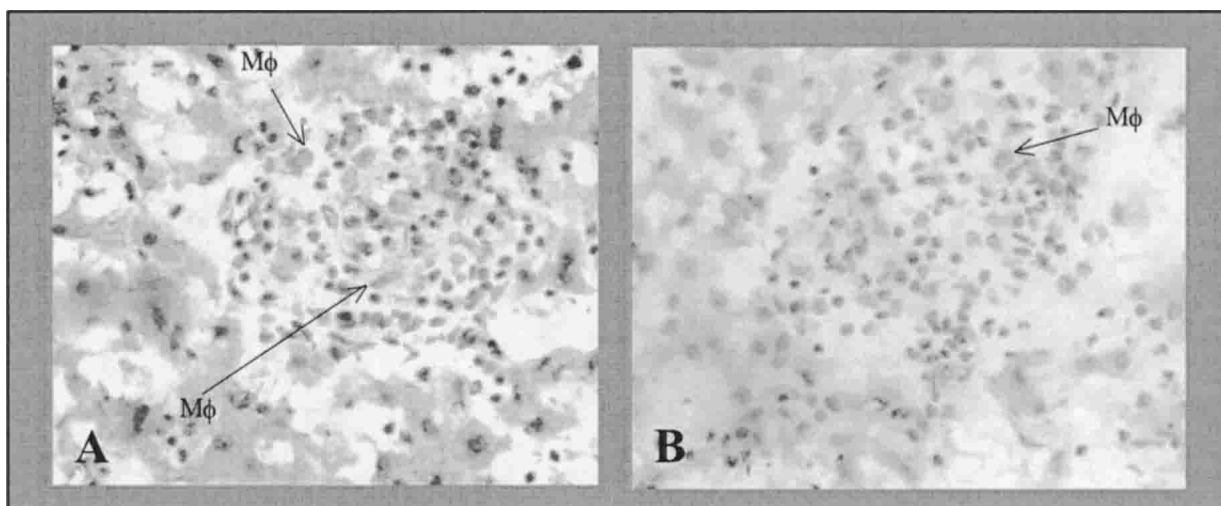


FIGURE 2. Differential hepatic immune response in asymptomatic and symptomatic dogs naturally infected with *Leishmania chagasi*. **A**, Hepatic reaction in an asymptomatic dog showing a well-organized granuloma with a central core of Kupffer cells surrounded by infiltrating lymphocytes. **B**, Hepatic reaction in a symptomatic dog showing a disorganized granuloma with dispersed Kupffer cells. Mφ = macrophage. (hematoxylin and eosin stained, magnification $\times 1,000$.)

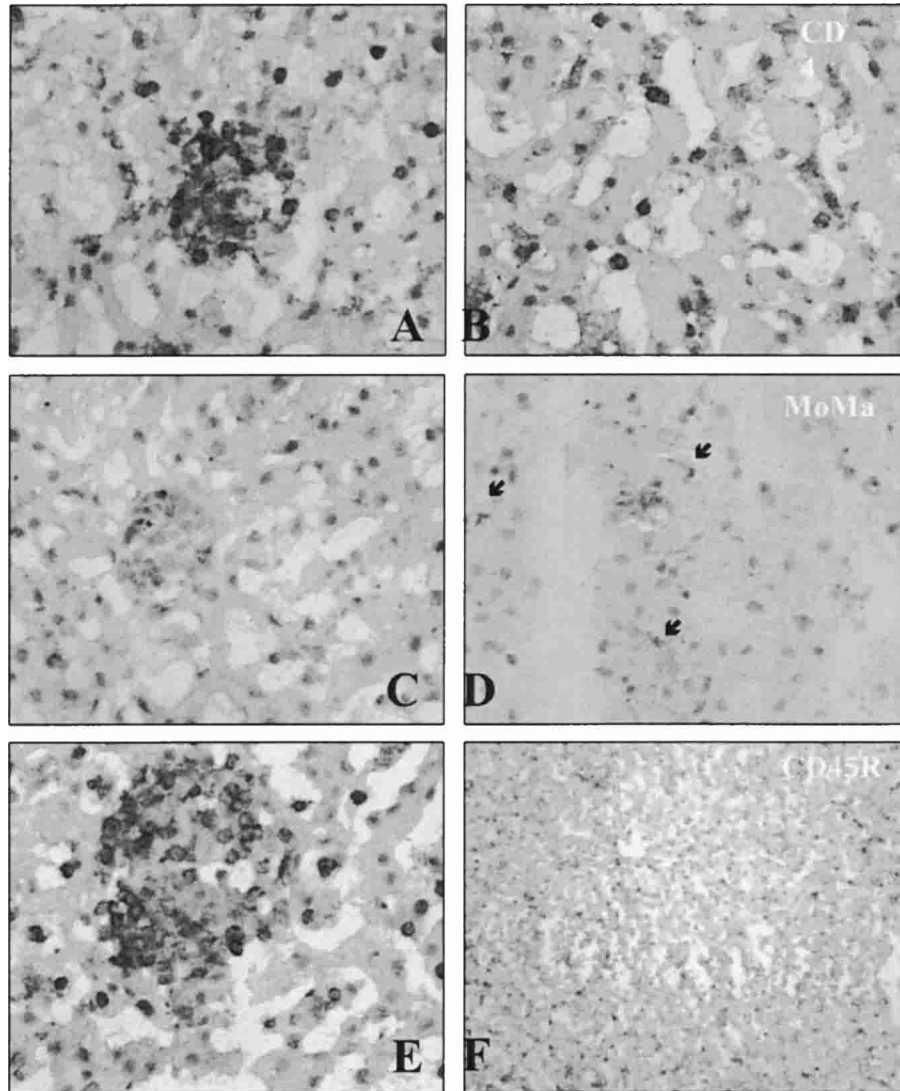


FIGURE 3. Immunocytochemical detection of leukocyte immunophenotypes in the livers of dogs naturally infected with *Leishmania chagasi*. **A**, CD4⁺ T cells are topographically organized in the granulomas in an asymptomatic dog. **B**, CD4⁺ T cells are randomly distributed through the hepatic sinusoids in a symptomatic dog. **C**, MoMa positive Kupffer cells are scarce in granulomas of asymptomatic dogs. **D**, Kupffer cells in a symptomatic dog are dispersedly distributed through the liver and are poorly labeled for monocytes-macrophages (**MoMa**). **Arrows** indicate MoMa-positive cells. **E**, Infiltrating CD45⁺ cells are focally localized in the hepatic granulomas in an asymptomatic dog. **F**, CD45R⁺ leukocytes are scattered and universally distributed through the liver. (Avidin-biotin immunoperoxidase stained, magnifications $\times 1,000$ in **A–E** and $\times 200$ in **F**.)

nificantly higher in asymptomatic dogs ($2,475 \text{ cells/mm}^2$) than in symptomatic dogs ($1,566 \text{ cells/mm}^2$) ($P \leq 0.05$).

Activated memory/effector immunophenotype in hepatic T cells in asymptomatic dogs. To characterize the role of T cells in canine VL in the target organs, mononuclear cell populations were isolated from livers and spleens of naturally infected dogs and analyzed by flow cytometry for the expression of activation molecules CD45RO and CD44. The results showed no differences between asymptomatic and symptomatic dogs in the numbers of memory, effector and naive T cell subsets in the spleen (Figure 6 and Table 1). In contrast, we observed remarkable differences in the liver, where distinct percentages of infiltrating CD44^{lo} CD45RO^{hi} central memory T cells were shown in asymptomatic (80.0 ± 12.0) and symptomatic (35.0 ± 12.0) dogs. Interestingly, many CD44^{lo}, CD45RO⁻ naive T cells were observed in the livers of symp-

tomatic dogs ($7.1 \pm 3.0\%$) compared with asymptomatic dogs ($0.2 \pm 0.2\%$).

DISCUSSION

The striking differences in parasite burdens between asymptomatic and symptomatic dogs naturally infected with *L. chagasi* suggest a diminished infection or a more efficient control of the parasite replication in asymptomatic dogs, especially since we ignored the exact time of infection. In addition, we observed more parasites per cell in the liver than in the spleen of all naturally infected dogs, which coincided with observations in mouse models of VL^{5,15} and other infections such as *Mycobacterium avium* infection of severe combined immunodeficient (SCID) mice, where bacterial growth con-

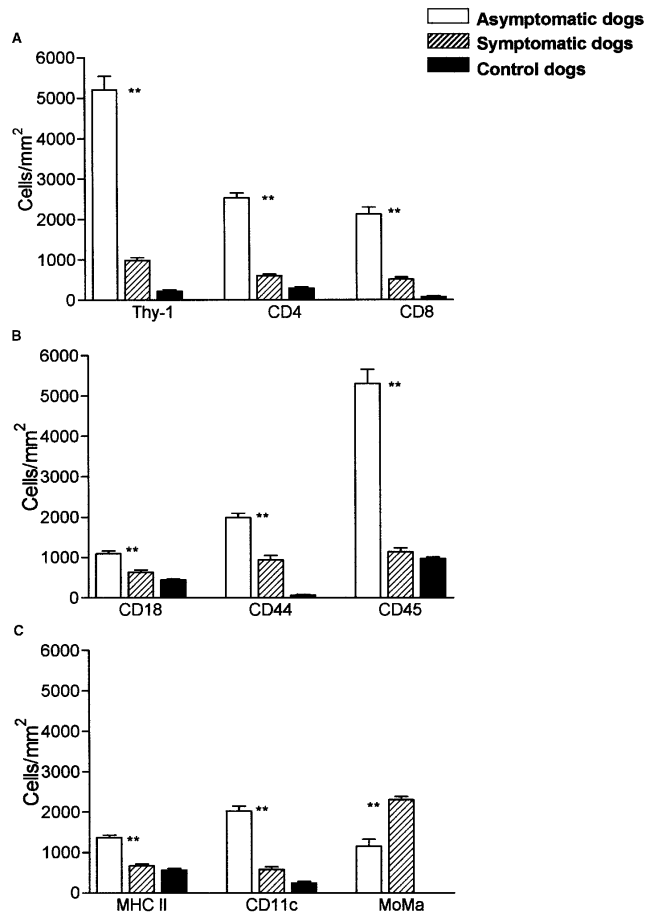


FIGURE 4. Density of leukocyte immunophenotypes in the livers of dogs naturally infected with *Leishmania chagasi*. **A**, Numbers of hepatic Thy-1+, CD4+, and CD8+ T cells are significantly higher in the livers of asymptomatic (n = 41) dogs compared with symptomatic (n = 19) dogs. **B**, Cells expressing the activation molecules CD18, CD44, and CD45RO are also increased in asymptomatic dogs. **C**, Despite the higher proportion of monocyte-macrophage (MoMa)-positive Kupffer cells in symptomatic dogs, the numbers of major histocompatibility class II (MHC II) cells and CD11c+ cells were reduced compared with those in asymptomatic dogs. Results are expressed as the mean \pm SEM of positive cells/mm² of liver. ***P* < 0.01 (n = 65).

tainment is achieved in the peritoneum and not in the spleen.¹⁶ Also, mice infected with *M. tuberculosis* can efficiently kill bacilli in the liver, spleen, and kidney, but not in the lung.¹⁷ Moreover, the immunolocalization of lipoarabinomannan, a component of mycobacterial surfaces associated with immunosuppression, is limited to the spleen marginal zone macrophages and to a lesser degree to hepatic resident macrophages (Kupffer cells).¹⁸ In the present study, similar observations were confirmed by quantifying the numbers of infected macrophages in histologic sections of canine liver and spleen.

The livers of asymptomatic dogs showed an effective immunity with well-organized granulomas walling off parasites in an environment of central memory and activated effector T cells, dendritic cells, and cells expressing CD18 and CD44. In contrast, livers from symptomatic dogs showed a non-organized and non-effective infiltrate composed of T cells and heavily parasitized Kupffer cells. Presumably, central memory

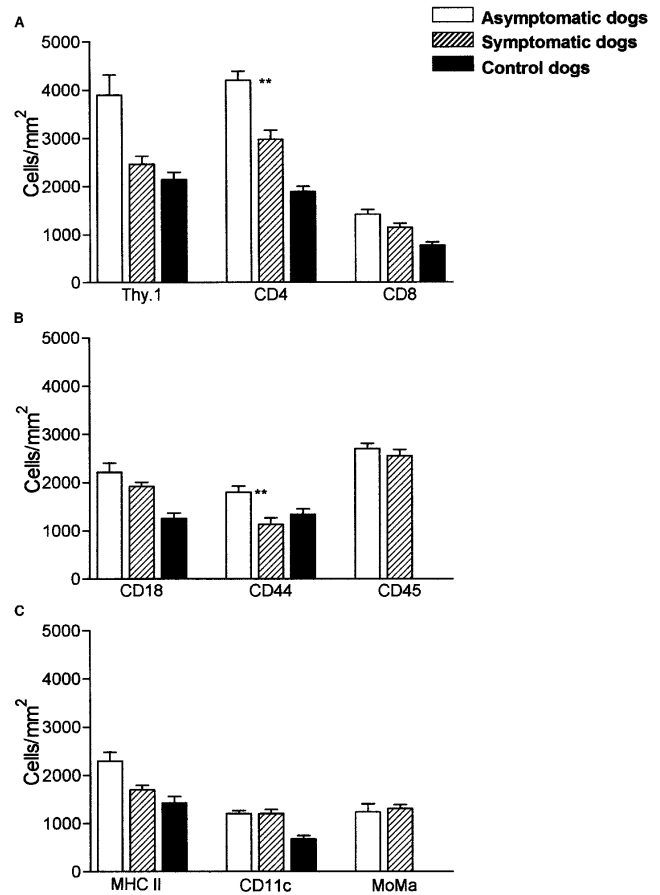


FIGURE 5. Density of leukocyte immunophenotypes in the spleens of dogs naturally infected with *Leishmania chagasi*. **A**, Similar numbers of T cells in asymptomatic (n = 41) and symptomatic (n = 19) dogs were demonstrated by the expression of Thy.1 and CD8 molecules with abundant CD4+ splenic T cells in asymptomatic dogs. **B**, The proportions of cells expressing the activation molecules CD18, CD44, and CD45RO were very similar in both groups. **C**, The proportions of antigen-presenting cells identified by the expression of major histocompatibility class II (MHC II) cells, CD11c+ cells, and monocyte-macrophage (MoMa)-positive cells were very similar in the spleens of both groups of dogs. Results are expressed as the mean \pm SEM of positive cells/mm² of spleen. ***P* < 0.01.

T cells are those sensitized against *L. chagasi* or other antigens. Moreover, the highest proportion of activated effector T cells was also observed in the liver of asymptomatic dogs, correlating with an effective immune response against the parasite. Interestingly, many naïve T cells were observed in the liver of symptomatic dogs. Mackay and others have demonstrated that ovine naïve T cells and memory T cells exhibit different patterns of migration.¹⁹ Thus, memory or effector T cells may migrate to peripheral tissues, providing protection at these vulnerable sites. In contrast, naïve T cells migrate almost exclusively to lymphoid organs, which are designed for receiving migrating cells and antigen sampling.^{19,20} Therefore, it is possible that the high proportion of naïve T cells found in the liver of symptomatic dogs correspond to a resident T cell group similar to that described in mice as a mixed T cell population associated with tolerance or non specific activation.²¹ Furthermore, these naïve T cells and the resting memory T cells may correspond to a pool of cells that selectively migrates to the liver to undergo apoptosis.^{22–24} How-

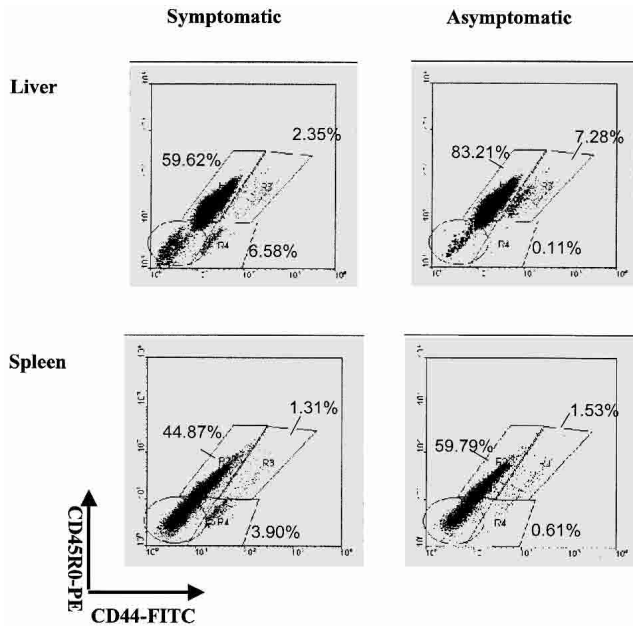


FIGURE 6. Flow cytometry analysis of activation molecules expressed by hepatic and splenic T cells isolated from dogs naturally infected with *Leishmania chagasi*. Shown is a correlative display of CD45RO–phycoerythrin (PE) and CD44–fluorescein isothiocyanate (FITC) in the livers and spleens of asymptomatic and symptomatic dogs. Notice the different proportions of central memory (CD44^{lo}, CD45RO^{hi}) (R2), activated effector memory (CD44^{hi}, CD45RO^{hi}) (R3), and naive (CD44^{lo}, CD45RO⁻) T cells (R4) in the livers and spleens of both groups. Results are from a single representative dog for each group.

ever, this issue may be addressed by verifying the expression of Fas-FasL, annexin V, and other apoptotic cell markers in the liver. Nevertheless, the role of naive T cells in the liver of infected dogs remains to be defined.

The lack of parasites or the low parasite burden observed in the mesenteric lymph nodes may be the result of a more efficient control of infection by this organ. This result is consistent with that observed in the mouse model, where a lower parasite burden in the lymph nodes than in the spleen corre-

sponds with a higher production of the proinflammatory cytokines interleukin-12 (IL-12) and interferon- γ (IFN- γ).²⁵ Since we lack information on the time span of infection from the dogs studied, it is impossible to determine the precise role of the lymph node in chronic canine VL and further studies with experimental dog models are necessary.

In the spleen, the immune responses of symptomatic and asymptomatic dogs were very similar. However, the selective accumulation of CD44⁺ and CD4⁺ T cells in the spleen of asymptomatic dogs is highly suggestive of an efficient cellular response against the parasite that involves the recruitment of parasite-specific CD4⁺ T cells destined to migrate to targets organs.

In contrast to our results, Tafuri and others in a histopathologic study of dogs in Brazil experimentally and naturally infected with *L. chagasi* observed intralobular granulomas in the livers of all the animals studied regardless the status of infection.¹² Moreover, consistent with our results, they observed a similar histologic pattern in the spleens of all the infected dogs, supporting the proposition of a differential response in target organs.

The participation of T lymphocytes in the control of infection with *Leishmania spp.* has been recognized and many studies with experimental models of cutaneous leishmaniasis and VL have demonstrated the importance of T cells in granuloma formation.^{5,26–28} Although it is impossible to predict the outcome of VL in naturally infected asymptomatic dogs, the results here presented showed well-defined hepatic granulomas with activated effector T cells, macrophages, and dendritic cells, and prominent expression of adhesion and activation molecules, suggesting the establishment of an efficient cell-mediated immunity that allows the infected animals to remain chronically infected but with a low parasite burden and undetectable clinical signs. Thus, this resembles the model of infection established in BALB/c and C57BL/6 mice, with a normal structure-normal function granuloma described by Murray.²⁹ In contrast, the lack of a mature hepatic granulomas and the marked decreased of infiltrating T cells and activation molecules in symptomatic dogs represents a no structure-no function granuloma, such as those observed in T cell-deficient mice (i.e., nude and SCID), monocyte influx-deficient mice (i.e., intercellular adhesion molecule 1 knock-out [KO]), and Th1-deficient mice (IL-12 KO and IFN- γ KO).²⁹ These differences in T cell distribution and function were less significant in the spleen, suggesting an organ-specific immune response in VL dogs, as described for the murine model.⁵

In canine VL, previous studies have focused on cytokine expression¹¹ and *in vitro* response of peripheral T cells.^{8,10,30} The present work is the first study in *L. chagasi*-infected dogs that addresses the role of T cells in target organs and shows a clear difference in the distribution of memory and effector T cells in the same individual and in the livers of asymptomatic dogs compared with symptomatic ones. These differences in the immune response to *Leishmania* should be taken in consideration in vaccine and drug development studies. Further investigation involving the expression of activation and regulatory molecules and the cytokine pattern in these target organs will provide a better knowledge of the regulation of the immune response in dogs against *Leishmania*.

TABLE 1

Percentage of T cell subsets determined by flow cytometry in the liver and the spleen of dogs naturally infected with *Leishmania chagasi**

	CD45RO ⁺ CD44 ^{lo} (Central memory)	CD45RO ^{hi} CD44 ^{hi} (Effector memory)	CD45RO ⁻ CD44 ^{lo} (Naive)
A			
Asymptomatic dog Liver (n = 6)	80.00 ± 12.00	6.00 ± 3.70	0.20 ± 0.20
B			
Symptomatic dog Liver (n = 5)	35.00 ± 12.00	2.60 ± 1.80	7.10 ± 3.00
C			
Asymptomatic dog Spleen (n = 6)	51.00 ± 19.00	1.60 ± 0.40	1.15 ± 0.93
D			
Symptomatic dog Spleen (n = 5)	59.00 ± 12.00	0.98 ± 0.60	2.43 ± 1.30
P†	A vs. B ≤0.001	A vs. B ≤0.01	A vs. B ≤0.001

* Values are the mean ± SD percentage of cells.
† Differences are statistically significant.

Acknowledgments: We are grateful to Dr. Marian Ulrich for comments on the manuscript, Dr. Dilia Brazon (Departamento de Dermatología Sanitaria de Nueva Esparta), Jose Luis García, Doris Belizario, Wilmer Galindo, and Sister Isolina Tomedes for their extraordinary support in collecting the samples and for field work, Dr. Pedro Rivas (Unidad de Cirugía Experimental, Escuela de Medicina Vargas, Caracas) for providing samples from healthy dogs, Dr. Pedro Sanchez and Patricia Rodriguez (Banco Municipal de Sangre) for help with the flow cytometry, and Richard Ramirez for technical assistance.

Financial support: This work was supported by Fondo Nacional de Ciencia, Tecnología e Innovación (FONACIT) Proyecto S1-2001000861 (Martin A. Sanchez), S1-98000041 (Felix J. Tapia), Millennium Scientific Initiative Grant 4572B, the European Commission International Cooperation with Third World Countries (INCO) Program, and the Consejo de Desarrollo Científico y Humanístico (CDCH)-Universidad Central de Venezuela (Felix J. Tapia).

Authors' address: Martin A. Sanchez, Nilka L. Diaz, Olga Zerpa, Emilia Negron, Jacinto Convit, and Felix J. Tapia, Laboratorio de Biología Molecular, Instituto de Biomedicina, Universidad Central de Venezuela, Apartado 4043, Caracas 1010A, Venezuela, Telephone: 58-212-862-9604, Fax 58-212-861-1258, E-mail: ftapia@telcel.net.ve.

REFERENCES

- WHO, 1996. *Tropical Disease Research—Progress 1995–1996*. Thirteenth Program Report of the UNDP/World Bank/World Health Organization Special Program for Research and Training in Tropical Diseases. Geneva: World Health Organization, 38–56.
- Torrealba JW, Amaral AD, Henriquez CE, Kowalenko W, Barrios PA, 1961. Observaciones iniciales sobre el perro (canis familiaris) como reservorio de kala-azar en Venezuela. *Rev Venezuela Sanidad Asistencia Soc* 26: 342–349.
- Zerpa O, Ulrich M, Negron E, Rodriguez N, Centeno M, Rodriguez V, Barrios RM, Belizario D, Reed S, Convit J, 2000. Canine visceral leishmaniasis on Margarita Island (Nueva Esparta, Venezuela). *Trans R Soc Trop Med Hyg* 94: 484–487.
- Wilson ME, Sandor M, Blum AM, Young BM, Metwali A, Elliott D, Lynch RG, Weinstock JV, 1996. Local suppression of IFN-gamma in hepatic granulomas correlates with tissue-specific replication of *Leishmania chagasi*. *J Immunol* 156: 2231–2239.
- Engwerda CR, Kaye PM, 2000. Organ-specific immune responses associated with infectious disease. *Immunol Today* 21: 73–78.
- Moreno J, Alvar J, 2002. Canine leishmaniasis: epidemiological risk and the experimental model. *Trends Parasitol* 18: 399–405.
- Moreno J, Nieto J, Chamizo C, Gonzalez F, Blanco F, Barker DC, Alva J, 1999. The immune response and PBMC subsets in canine visceral leishmaniasis before and after chemotherapy. *Vet Immunol Immunopathol* 71: 181–195.
- Pinelli E, Rutten VP, Bruysters M, Moore PF, Ruitenber EJ, 1999. Compensation for decreased expression of B7 molecules on *Leishmania infantum*-infected canine macrophages results in restoration of parasite-specific T-cell proliferation and gamma interferon production. *Infect Immun* 67: 237–243.
- Solano-Gallego L, Llull J, Ramos G, Riera C, Arboix M, Alberola J, Ferrer L, 2000. The Iberian hound presents a predominantly cellular immune response against natural *Leishmania* infection. *Vet Parasitol* 90: 37–45.
- Pinelli E, Killick-Kendrick R, Wagenaar J, Bernadina W, del Real G, Ruitenber J, 1994. Cellular and humoral immune responses in dogs experimentally and naturally infected with *Leishmania infantum*. *Infect Immun* 62: 229–235.
- Quinnell RJ, Courtenay O, Shaw MA, Day MJ, Garcez LM, Dye C, Kaye PM, 2001. Tissue cytokine responses in canine visceral leishmaniasis. *J Infect Dis* 183: 1421–1424.
- Tafari WL, Barbosa AJ, Michalick MS, Genaro O, Franca-Silva JC, Mayrink W, Nascimento E, 1996. Histopathology and immunocytochemical study of type 3 and type 4 complement receptors in the liver and spleen of dogs naturally and experimentally infected with *Leishmania (Leishmania) chagasi*. *Rev Inst Med Trop Sao Paulo* 38: 81–89.
- Zerpa O, Pratloug F, Ulrich M, Convit J, 2001. Isolation of *Leishmania infantum*, zymodeme MON-1 from canine and human visceral leishmaniasis on Margarita Island, Venezuela. *Mem Inst Oswaldo Cruz* 96: 901–902.
- Kaye PM, Bancroft GJ, 1992. *Leishmania donovani* infection in acid mice: lack of tissue response and *in vivo* macrophage activation correlates with failure to trigger natural killer cell-derived gamma interferon production *in vitro*. *Infect Immun* 60: 4335–4342.
- Cotterell SE, Engwerda CR, Kaye PM, 1999. *Leishmania donovani* infection initiates T cell-independent chemokine responses, which are subsequently amplified in a T cell-dependent manner. *Eur J Immunol* 29: 203–214.
- Murray HW, Masur H, Keithly JS, 1982. Cell-mediated immune response in experimental visceral leishmaniasis. I. Correlation between resistance to *Leishmania donovani* and lymphokine-generating capacity. *J Immunol* 129: 344–350.
- Bloom BR, Flynn J, McDonough K, Kress Y, Chan J, 1994. Experimental approaches to mechanisms of protection and pathogenesis in *M. tuberculosis* infection. *Immunobiology* 191: 526–536.
- Glatman-Freedman A, Mednick AJ, Lendvai N, Casadevall A, 2000. Clearance and organ distribution of *Mycobacterium tuberculosis* lipoarabinomannan (LAM) in the presence and absence of LAM-binding immunoglobulin M. *Infect Immun* 68: 335–341.
- Mackay CR, Marston WL, Dudler L, 1990. Naive and memory T cells show distinct pathways of lymphocyte recirculation. *J Exp Med* 171: 801–817.
- Mackay CR, Marston WL, Dudler L, Spertini O, Tedder TF, Hein WR, 1992. Tissue-specific migration pathways by phenotypically distinct subpopulations of memory T cells. *Eur J Immunol* 22: 887–895.
- O'Farrelly C, Crispe IN, 1999. Prometheus through the looking glass: reflections on the hepatic immune system. *Immunol Today* 20: 394–398.
- Crispe IN, Huang L, 1994. Neonatal, moribund and undead T cells: the role of the liver in T cell development. *Semin Immunol* 6: 39–41.
- Huang L, Soldevila G, Leeker M, Flavell R, Crispe IN, 1994. The liver eliminates T cells undergoing antigen-triggered apoptosis *in vivo*. *Immunity* 1: 741–749.
- Crispe IN, Dao T, Klugewitz K, Mehal WZ, Metz DP, 2000. The liver as a site of T-cell apoptosis: graveyard or killing field? *Immunol Rev* 174: 47–62.
- Melby PC, Yang YZ, Cheng J, Zhao W, 1998. Regional differences in the cellular immune response to experimental cutaneous or visceral infection with *Leishmania donovani*. *Infect Immun* 66: 18–27.
- Murray HW, Squires KE, Miralles CD, Stoeckle MY, Granger AM, Granelli-Piperno A, Bogdan C, 1992. Acquired resistance and granuloma formation in experimental visceral leishmaniasis. Differential T cell and lymphokine roles in initial versus established immunity. *J Immunol* 148: 1858–1863.
- Reiner SL, Wang ZE, Hatam F, Scott P, Locksley RM, 1993. TH1 and TH2 cell antigen receptors in experimental leishmaniasis. *Science* 259: 1457–1460.
- Reiner SL, Locksley RM, 1995. The regulation of immunity to *Leishmania major*. *Annu Rev Immunol* 13: 151–177.
- Murray HW, 2001. Tissue granuloma structure-function in experimental visceral leishmaniasis. *Int J Exp Pathol* 82: 249–267.
- Pinelli E, Gebhard D, Mommaas AM, van Hoeij M, Langermans JA, Ruitenber EJ, Rutten VP, 2000. Infection of a canine macrophage cell line with *Leishmania infantum*: determination of nitric oxide production and anti-leishmanial activity. *Vet Parasitol* 92: 181–189.