

Application of phosphocreatine in the treatment of a patient with acute myocardial infarction on the background of auxiliary circulation

Aplicación de la fosfocreatina en el tratamiento de un paciente con infarcción miocárdica aguda en el antecedentes de la circulación auxiliar

Larisa V. Shekhovtsova¹, Ekaterina A. Artemova², Olga A. Osipova³, Andrey I. Golovin⁴

¹The Belgorod state national research university, Belgorod, Russia (Pobedy St. 85, Belgorod, Russia, 308015); <https://orcid.org/0000-0002-1033-814X>

²Belgorod State University, Belgorod, Russia (85, Pobedy Str., Belgorod, Russia, 308015); <https://orcid.org/0000-0003-1710-2487>

³LLC CLINIC of HEART, Sary Oskol, Russia (Komsomolsky Avenue 81, Sary Oskol, Russia, 309504); <https://orcid.org/0000-0002-6487-9822>

⁴LLC HEART CLINIC, Sary Oskol, Russia (81, Komsomolsky Avenue, Sary Oskol, Russia, 309504); <https://orcid.org/0000-0001-5272-7509>

*corresponding author: Larisa V. Shekhovtsova, "The Belgorod state national research university", Belgorod, Russia. Email: shekhovtsova_l@mail.ru

270

Abstract

The clinical case of maintaining the patient with a sharp transmural myocardial infarction front septal areas and tops of the left ventricle, the cardiogenic shock of the II degree and alveolar hypostasis of lungs are described. In the treatment of the patient auxiliary blood circulation in the form of installation of an intra aortal balloon counterpulsation in the descending department of an aorta was applied. Also, phosphocreatine (PCR) of 8 g once with the subsequent appointment on 2 g twice a day which has the expressed cardioprotective and antiarrhythmic effect in addition to standard therapy in the first days of disease was appointed.

Keywords: phosphocreatine, myocardial infarction, intra aortal balloon counterpulsation.

Introduction

In the practical work of the cardiologist cases when despite observance of all modern approaches described in clinical recommendations for stabilization of a condition of the patient it is necessary to be beyond standards¹ meet. The use of additional resources can help to bring the patient out of critical condition, to thereby save his life. One of such medicines is Phosphocreatine (PCR)^{2,3}. Preservation of myocardium of acute myocardial infarction (AMI) - the major clinical task on which solution the next and remote forecast for the patient depends. The extensiveness of myocardial infarction (AMI) - the main reason for the development of heavy arrhythmias and heart failure⁴. Pilot and clinical trials of biochemical processes at ischemia of a myocardium showed a decrease of cardiomyocytes (CM) of the level of energy-rich phosphates what as Phosphocreatine (PCr) and adenosine triphosphate (ATPH)⁵. This decrease correlates with the weight of structural and functional injuries of a myocardium. On this basis, the set of researches of assessment of the cardioprotective effect of exogenous Phosphocreatine (PCr) is conducted⁶.

Phosphocreatine (PCr) plays an important role in the metabolism of cells, being an irreplaceable power source and adenosine triphosphate (ATPH)⁷. The set of researches confirmed that Phosphocreatine (PCr) exerts a positive impact on the metabolism of the energy of a myocardium, improving excitability, conductivity, and contractility of cardiomyocytes (CM), thereby minimizing the risk of developing of arrhythmia and keeping the contractile ability of a myocardium⁸.

Fibrosis of myocardium is the leading pathological change at an acute myocardial infarction (AMI) and is characterized by the excessive adjournment of extracellular matrix (ECM)⁹. Fibrosis of a cardiac muscle leads to the development of diastolic dysfunction (DD) of the left ventricle

Resumen

Se describe el caso clínico de mantener al paciente con un infarto transmural agudo en las áreas septales frontales y en la parte superior del ventrículo izquierdo, el shock cardiogénico de grado II y la hinchazón alveolar de los pulmones. En el tratamiento del paciente se aplicó circulación de sangre auxiliar en forma de instalación de contrapulsación con balón intraaórtico en el departamento descendente de una aorta. También se nombró fosfocreatina (PCR) de 8 g una vez con la siguiente cita en 2 g dos veces al día, que tiene el efecto cardioprotector y antiarrítmico expresado además de la terapia estándar en los primeros días de la enfermedad.

Palabras clave: Fosfocreatina, infarto de miocardio, contrapulsación con balón intraaórtico.

(LV), different developing of arrhythmias, followed by progressing heart failure (HF)^{5,7}. Fibroblast of a myocardium, being the most widespread cell type, play a crucial role in the course of fibrosis. Interaction of factors of inflammation and cytokine contributes to the continuous development of fibrosis of a myocardium. The modern cardiology is concentrated on delay, prevention, regression of fibrosis of heart, but effective methods of treatment and today practically does not exist^{10,11}.

For patients with acute myocardial infarction (AMI) the cause of death of cardiomyocytes (CM) is their apoptosis. A large number of research works proved that apoptosis of cardiomyocytes (CM) is the key moment in progressing heart failure (HF) at various diseases of the heart^{1,12,13}.

The positive effect of Phosphocreatine (PCr) at the development of fibrosis of a cardiac muscle was exposed to scientific consideration in experiments on animals^{10,11}. So, the Chinese scientific Dai H, Chen L, etc. researched rats for studying of influence of Phosphocreatine (PCr) on myocardium fibrosis. For induction of fibrosis of a myocardium at animals used Isoproterenol (ISO)¹⁴. Reference 14: Osipova, O. A., et al. Not Dai H, Chen L, Phosphocreatine (PCr) entered at the following stage of an experiment suppressed apoptosis of cardiomyocytes (CM) that led to the reduction of the severity of fibrosis due to the reduction of accumulation of collagen and the related markers. Their activity was high after Isoproterenol activation (ISO) and the cancellation of the introduction of Phosphocreatine (PCr) that proved a possibility of its use as the means of preventing myocardium fibrosis.

According to the meta-analysis of 23 controlled types of research with the participation of 3400 patients Phosphocreatine (PCr) authentically reduces the general lethality, prevents the development of complications of acute myocardial infarction (AMI) and chronic heart failure of chronic heart failure (CHF)³.

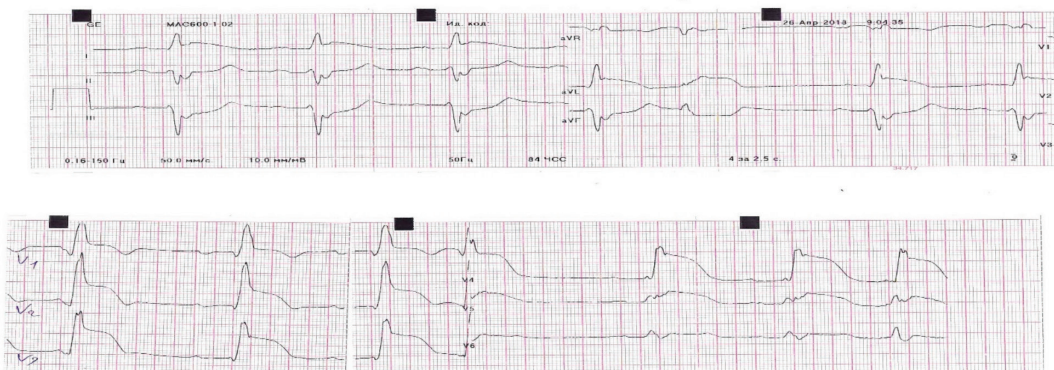
Main Part: Our clinical case can serve as an example of a positive effect on the use of phosphocreatine (PCr).

Patient N., 76 years, came to Head of Intensive cardiac care unit, "Heart Clinic" Ltd on April 26, 2018. It is delivered by a crew of emergency medical service in critical condition with complaints to the pains expressed press-

ing, squeezing behind a breast irradiating in the left hand which is followed by the sharp general weakness expressed by short wind, cold sticky then. From the anamnesis it is found out: the above-stated complaints arose suddenly about 6 h 30 min. 26.04.2018 at rest. The crew of emergency medical service on the electrocardiogram (ECG) recorded ST-segment elevation to 3 mm in assignments of V2-V5. With suspicion of acute myocardial infarction (AMI) the patient is brought to LLC Clinic of Heart "Heart Clinic" Ltd for carrying out of coronary angiography (CAG) and the solution of a question of further tactics of treatment. According to the patient, about 5 years have hypertension with the maximum figures of arterial pressure (AP) of 170/90 mm Hg. did not take hypotensive drugs regularly. Within the last six months noted episodes of the short-term pressing pains behind a breast three times. We were stopped independently at rest. In medical institutions did not ask for medical care.

At objective survey: consciousness of the patient is confused, is periodically disoriented in the place and time. Normosthenic constitution, moderate food. Integuments and visible mucous pale. The mottled acrocyanosis, the increased humidity of integuments is observed. Auxiliary muscles, the percutaneous - overall surface of lungs a pulmonary sound participate in the act of breathing. Breathing rate (BR) 26 in a minute, SpO2 84%. Auscultatory rigid breath weakened in the lower departments of lungs, damp mixed rattles in the lower and average departments on both sides in a large number. Veins necks bulk up. Tones of heart rhythmical, are muffled, the noise has not listened. Easing of the I tone is observed. Heart rate (HR) of 98 beats per minute. Arterial pressure (AP) = 85/55 mm Hg. Language is damp, it is not laid over. The stomach of the correct form, symmetric, evenly participates in the act of breath, at a palpation soft, painless. The liver, a spleen is not palpated. Active vermicular movement. The lumbar area is visually not changed, a beating symptom negative on both sides. Peripheral hypostases are absent. At revenues to an electrocardiogram (ECG) (fig. 1) against the background of a sinus rhythm, the complete blockade of the right bundle of His, ST-segment elevation to 9 mm in assignments of V2-V5 is recorded. In the general blood test, it is noted leucocytosis 13,13x10⁹/l. In biochemical blood test - increase in cardio specific enzymes: troponin I - 5,53ng/ml.

Fig. 1. ECG on admission



The clinical picture was regarded as a sharp transmural myocardial infarction front septal areas and tops of LV, complicated by the cardiogenic shock of the II degree and alveolar hypostasis of lungs. At a stage of ambulance medical care - statement of an intravenous catheter in a cubital vein of the top left extremity is provided, oxygen therapy, intravenous administration of heparin of 4000 Pieces, are orally given load doses of antiaggregant (acetylsalicylic acid of 300 mg, clopidogrel 600 mg). In a hospital correction of acute left ventricular failure (ALVF) - intravenous support with inotropic medicines (a dopamine, dobutamine) under control of indicators of hemodynamics, intravenous bolus administration of furosemide with the subsequent infusion through a perfusion under control of a diuresis, intravenous administration of morphine with the anesthetizing purpose is immediately begun and for unloading of a small circle of blood circulation, the uric catheter is established.

According to the emergency indications, the patient is brought in an X-ray operating room for carrying out CAG with possible implantation of the stent in a symptom - the connected artery for the restoration of blood supply of a myocardium. On coronary angiography (CAG) (fig. 2) occlusion of a proximal third of left anterior descending artery (LAD), decides on lack of contrasting of the distal course, a stenosis of 40% in an average third of the left circumflex coronary artery (LCX), the left type of coronary blood supply.

The decision to execute a recanalization of occlusion of the left ventricle (LAD) with the subsequent stenting is made. It is implanted a stent to Multi-Link (D - 4mm, L-28mm). On a control angiography (CAG) (fig. 3, 4) filling of distal departments of the left anterior descending artery (LAD) - TIMI 2.

Considering unstable hemodynamics, not stopped swelled lungs, in the descending department of an aorta of intra-aortic balloon counter-pulsator (IABCS) is established. The patient is transferred to the chamber of intensive therapy. Against the background of the carried-out therapy within the first days' complaints to the moderate pressing pains behind a breast, the expressed short wind, unproductive cough, clinic of acute left ventricular failure (ALVF), instability of hemodynamics remained.

In the first days of hospitalization, there was a failure of a warm rhythm in atrial fibrillation (AF) to heart rate (HR) from 100 to 134 bt. a minute. To ensure adequate infusion of medicines and control of the central venous pressure, the catheterization of the right jugular vein is made. Correction of acute left ventricular failure (ALVF) by intravenous administration of inotropic medicines (a dopamine, dobutamine) under control of indicators of hemodynamics, the intravenous dosed administration of loopback diuretics (furosemide) under control of indicators of a diuresis, adequate anesthesia by narcotic analgesics is continued (fentanyl, morphine, promedol), for the purpose of prevention of a further clottage intravenous

infusion of heparin under control of ALVF and clot time is begun, for restoration of a sinus rhythm and prevention of life-threatening violations of a rhythm (fibrillation of ventricles) intravenous infusion of an amiodaron under control of indicators of hemodynamics and control of the electrocardiogram (ECG) on the cardio monitor is begun. At an echocardiography fraction of emission of left ventricular ejection fraction (LVEF) = 31%

Considering not stopped left ventricular failure (LVF), the remaining picture of cardiogenic shock with the cardioprotective purpose could be added to therapy Phosphocreatine (PCr) 8 g once with the subsequent appointment on 2 g twice a day.

27.04.2018 some positive dynamics are noted - anginozic pains were stopped, a short wind at rest considerably decreased, the sinus rhythm was restored. Tones of heart rhythmical, are muffled. Arterial pressure (AP) 108/62mm hg, of heart rate (HR) 91 bt. in a minute. Considerable reduction of damp small-bubble rattles in the lower departments of lungs was noted. Breathing rate (BR) 20 a minute. SpO2 90-95%. Work of IABCS, hemodynamics support as an infusion of vasoconstrictor was continued. At a control echocardiography increase in the global contractive ability of a myocardium up to 35% is noted. The course of treatment Phosphocreatine (PCr) on 2 g twice a day is continued.

29.04.2018 - permanent stabilization of hemodynamics, on electrocardiograms (ECG) a steady sinus rhythm. IABCS is removed. Tones of heart rhythmical, are muffled, AP within a day within 100-114/60-68 mm Hg, HR within 100 bt. in a minute. In lungs single damp small-bubble rattles in the lower departments of lungs on both sides. Breathing rate (BR) within 20-22 in a minute, SpO2 92 without oxygen insufflation. The speed of the infusion of vasoconstrictor is reduced. At control, biochemical blood test reduction of indicators of cardio specific markers is noted. At echocardiography - an increase in the global contractive ability of a myocardium - FV of 39%. The course of treatment Phosphocreatine (PCr) on 2 g twice a day is continued.

1.05.2018 infusion of vasoconstrictor is gradually stopped. The patient gradually becomes more active. Anginozic pains do not recur, notes the feeling of shortage of air at the minimum physical activity. Tones of heart rhythmical, are muffled. AD within a day = 97-100/60-70 mm Hg., TSS = 94-98 bt. in a minute. In lungs single crepitant in the lower departments of lungs on both sides, ChDD - 18 in a minute, SpO2 92-98%. On control EHO-KG - without negative dynamics, an increase in the global contractive ability of a myocardium - LVEF of 41% is noted. The course of treatment Phosphocreatine (PCr) on 2 g twice a day is continued.

Against the background of the carried-out therapy the condition of the patient was stabilized, is made active on the ward mode. During the period from 3.05.2018 to

7.05.2018 a state with positive dynamics. The patient is made active on the IIB mode. Anginal pains did not recur, notes the feeling of shortage of air at the minimum physical activity. In lungs developments of stagnation in the form of crepitant rattles in the lower departments of lungs remain. Hemodynamics is stable. At control blood

test normalization of the level of leukocytes of blood is observed ($8,1 \times 10^9/l$). In biochemical blood test normalization of cardio specific markers. On the electrocardiogram (ECG) (fig. 5) - a rhythm sinus, violations of a warm rhythm did not repeat from the date of the purpose of Phosphocreatine (PCr). LVEF = 45%.

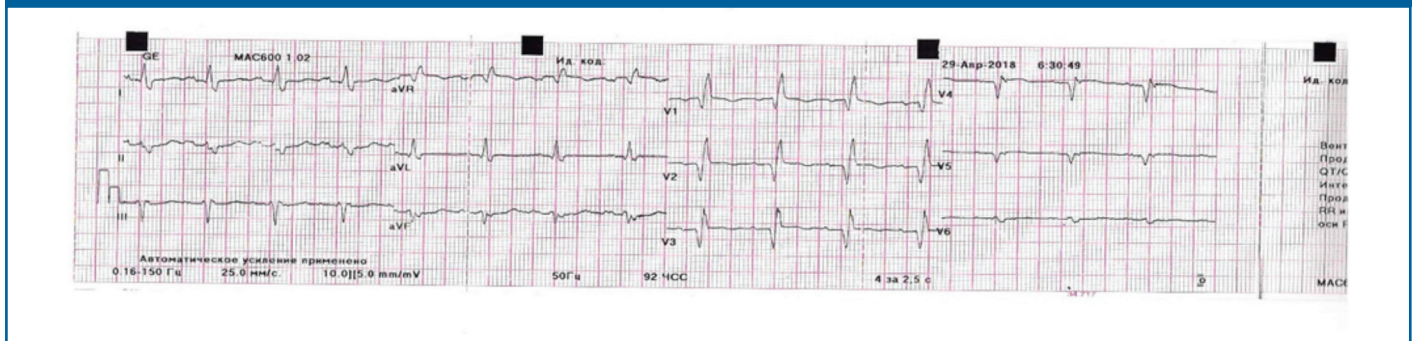
Fig. 2. Initial coronary angiography

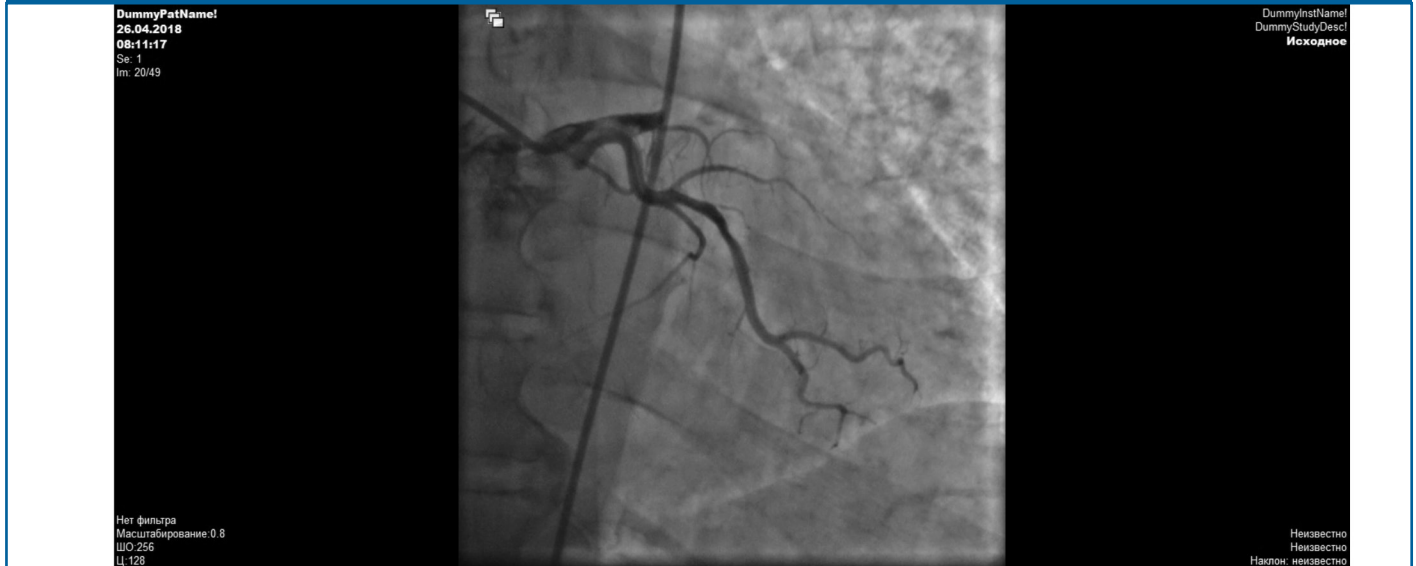

Fig. 3, 4. Control of coronary angiography.

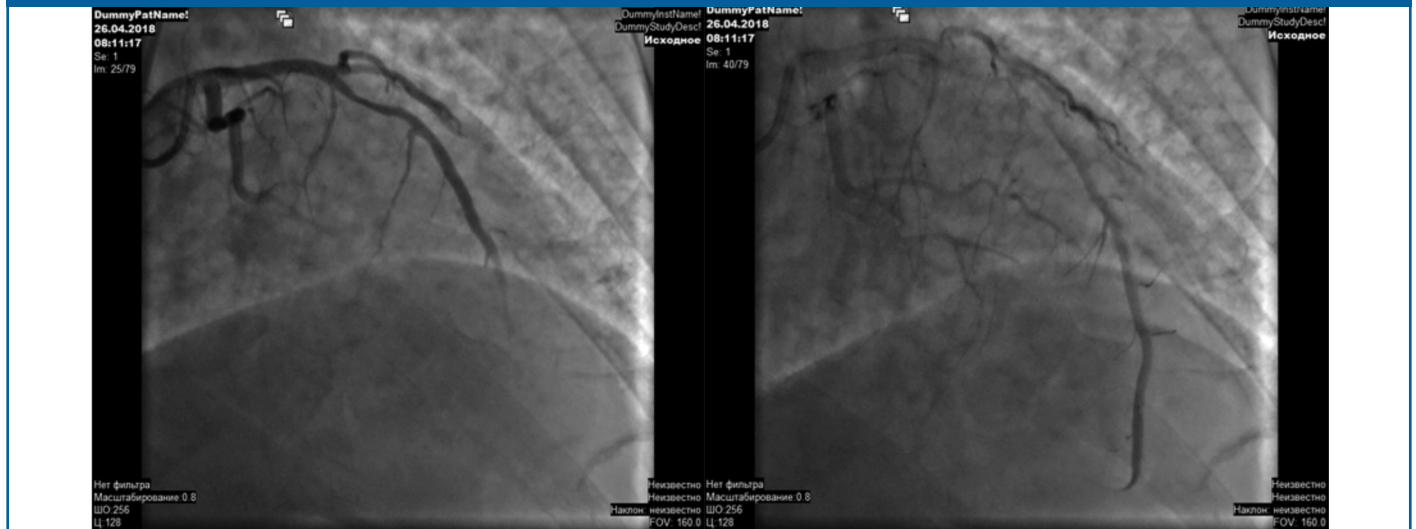

Fig. 5. ECG at discharge



In the presented clinical case of maintaining the patient with a sharp transmural myocardial infarction front septal areas and tops of the left ventricle, cardiogenic shock of the II degree and alveolar hypostasis of lungs, Phosphocreatine (PCr) has the expressed cardioprotective and antiarrhythmic effect at addition to standard therapy of an acute myocardial infarction (AMI) in the first days of a disease, including against the background of carrying out auxiliary blood circulation.

References

- Gong, H., Lyu, X., Wang, Q., Hu, M., Zhang, X., 2017. Endothelial to mesenchymal transition in the cardiovascular system. *Life Sciences*. 2017;184:95-102.
- Giovanni, L., Alberto, Z., Cardiac protection with phosphocreatine: A meta-analysis. *Interactive CardioVascular and Thoracic Surgery*, Advance Access published June 17; 2016: 1-10.
- Kong, P., Christia, P., Frangogiannis, N. G. The pathogenesis of cardiac fibrosis. *Cellular and Molecular Life Sciences*. 2014;71(4):549-574.
- Spinale, F.G. Myocardial matrix remodeling and the matrix metalloproteinases: influence on cardiac form and function. *Physiological Reviews*. 2007;87(4):1285-1342.
- Rockey, D.C., Bell, P.D., Hill, J.A. Fibrosis-a common pathway to organ injury and failure. *The New England Journal of Medicine*. 2015; 372 (12): 1138-1149.
- Zeisberg, E. M., Tarnavski, O., Zeisberg, M. Endothelial-to-mesenchymal transition contributes to cardiac fibrosis. *Nature Medicine*. 2007;13(8):952-961.
- Guimarães-Ferreira, L. Role of the phosphocreatine system on energetic homeostasis in skeletal and cardiac muscles. *Einstein (São Paulo)*. 2014;12(1):126-131.
- Osipova, O. A., Shekhovtsova L. V., Petrov, G. D. Mechanisms of formation of chronic heart failure at an early stage of its development in patients with postinfarction cardiosclerosis/Scientific peer-reviewed journal "Scientific Bulletin of the Belgorod State University". 2015; 4 (201): 29:16-19 (in Russian).
- Gottlieb, R.A., Burleson, K.O., Kloner, R.A. Reperfusion injury induces apoptosis in rabbit cardiomyocytes. *The Journal of Clinical Investigation*. 1994; 94(4):1621-1628.
- Di Gregorio, G., De Sanctis, F., Di Napoli, P. Myocardium-protective effects of phosphocreatine in experimental ischemia-reperfusion. *Cardiology*. 1992; 37(2):135-140.
- Klingberg, F., Hinz, B., White, E. S. The myofibril area matrix: Implications for tissue repair and fibrosis. *The Journal of Pathology*. 2013; 229(2):298-309.
- Takemura, G., Kanoh, M., Minatoguchi, S., Fujiwara, H. Cardiomyocyte apoptosis in the failing heart-a critical review from definition and classification of cell death. *International Journal of Cardiology*. 2013; 167(6):2373-2386.
- Perepech, N. B., Nedoshivin, A. O., Kutuzova, A. E. Exogenous phosphocreatine in the prevention and treatment of cardiac insufficiency in patients with myocardial infarction. *Klinicheskaia Meditsina*. 1993; 19-22.
- Osipova, O. A., Nagibina, A. I., Komisov, A. A. Pathomorphologic mechanisms of regulation of the formation of myocardial fibrosis at patients with chronic heart failure against the background of coronary heart disease. *Serdechnaya Nedostatochnost magazine*. 2016;17(5):357-364 (in Russian).

Manuel Velasco (Venezuela) **Editor en Jefe** - Felipe Alberto Espino Comercialización y Producción
Reg Registrada en los siguientes índices y bases de datos:

WEB OF SCIENCE (WOS)

SCOPUS, EMBASE, Compendex, GEOBASE, EMBiology, Elsevier BIOBASE, FLUIDEX, World Textiles,

OPEN JOURNAL SYSTEMS (OJS),

REDALYC (Red de Revistas Científicas de América Latina, el Caribe, España y Portugal),

Google Scholar

LATINDEX (Sistema Regional de Información en Línea para Revistas Científicas de América Latina, el Caribe, España y Portugal)

LIVECS (Literatura Venezolana para la Ciencias de la Salud), LILACS (Literatura Latinoamericana y del Caribe en Ciencias de la Salud)

PERIÓDICA (Índices de Revistas Latinoamericanas en Ciencias), REVENCYT (Índice y Biblioteca Electrónica de Revistas Venezolanas de Ciencias y Tecnología)

SABER UCV, DRJI (Directory of Research Journal Indexing)

CLaCALIA (Conocimiento Latinoamericano y Caribeño de Libre Acceso), EBSCO Publishing, PROQUEST



Esta Revista se publica bajo el auspicio del
Consejo de Desarrollo Científico y Humanístico
Universidad Central de Venezuela.



cdch-ucv.net

publicaciones@cdch-ucv.net

WWW.REVHIPERTENSION.COM

WWW.REVDIABETES.COM

WWW.REVSINDROME.COM

WWW.REVISTA AVFT.COM